

Scientific Journal of the Faculty of Medicine in Niš 2012;29(3):125-131

Original article ■

Value of the First Examination for Developmental Dysplasia of the Hip - Our Experiences

Predrag Grubor¹, Milan Grubor², Marinko Domuzin¹, Ivan Golubovic³

¹Traumatology Clinic, Clinical Centre Banja Luka, Bosnia and Herzegovina

²School of Medicine Banja Luka, Bosnia and Herzegovina

³Traumatology Clinic, Clinical Centre Niš, Serbia

SUMMARY

Developmental dysplasia of the hip (DDH) means a distinct dislocation (lateralisation and cranialisation) of the femoral head from the poorly developed (hypoplastic and steeper) acetabulum.

The aim of the paper was to establish, in a retrospective and prospective study conducted in the period between January 1, 2006 and December 31, 2010, the total number and characteristics of instances of DDH in the first clinical and ultrasound examinations in newborns examined at the Traumatology Clinic of the Clinical Centre in Banja Luka.

Six thousand one hundred thirty-two children were examined and 99 were treated. The percentage of girls among the treated children was considerably higher (96%). The ultrasound examination was performed first and was followed by the clinical examination. The ultrasound examination of all babies was performed with an electronic 5-12-MHz probe, using the standard Graf's method.

7.8% of the cases, mostly primiparae, had a positive family history of DDH. The incidence diagnosed clinically amounted to 8.87%, and the incidence diagnosed by ultrasound to 1.61%. The first clinical examination diagnosed a limited abduction of the right hip in 12.1% of the newborns, while limited abduction of the left hip was present in 96.0%. Ortolani's sign in the right hip was positive in 3.0% and in 33.3% patients it was positive in the left hip. 3.0% of the newborns had a positive Palmen sign in the right hip in the first examination, and 42.4% in the left. 3% of the patients had asymmetric skin creases on the right upper leg, while 87.9% of the patients had them on the left upper leg. 46.5% of the patients had crepitations in their right hip, while 83.8% had crepitations in the left hip. 2% of the patients had a lax right hip, while 3% had a lax left hip. The results obtained from the ossified acetabulum of the right hip in the examined sample were as follows: good in 91.9%, satisfactory in 5.1%, insufficient (deficient) in 2.0%, and bad in 1.0% of the cases. The results from the left ossified acetabulum were as follows: good in 3.0%, satisfactory in 44.4%, insufficient (deficient) in 45.5%, bad in 7.1% of the cases. The bony protrusion - acetabular labrum on the right hip was angular in 90.9%, obtuse (fused) in 1.0%, round in 7.1%, round to flat and flat in 1.0% of the cases. The bony protrusion - acetabular labrum on the left hip was angular in 2.0%, obtuse (fused) in 2.0%, round in 81.8%, round to flat and flat in 14.1% of the cases.

It is important to commence with diagnosing and treating DDH as early as possible by applying atraumatic aids and procedures while all structures are elastic, reducible and adaptable.

The clinical examination is unreliable in terms of diagnosis of DDH, but it is mandatory as a part of the full physical examination of a newborn baby.

Key words: developmental dysplasia of the hip, ultrasound

Corresponding author:

Predrag Grubor •

phone: 00 387 51 221 360 •

e-mail: predraggrubor@gmail.com •

INTRODUCTION

Developmental dysplasia of the hip (DDH) means a distinct dislocation (lateralisation and cranialisation) of the femoral head from the poorly developed (hypoplastic and steeper) acetabulum (1). The term 'developmental dysplasia of the hip' (DDH) is the most adequate as it encompasses all levels in the development of this malformation and all ages in a child's development (2, 3). The conditions for DDH are created during intrauterine life when the hip is predominantly cartilaginous, and the head is encompassed by a shallow acetabulum. The joint capsule is lax and intrauterine pressure is transferred onto the greater trochanter in one of the luxated positions (4, 5). If the hip has been flexed for a longer period, changes take place in the soft tissues as well. The joint capsule extends, along with the ligament of the head of the femur, which becomes thickened as well. The pelvotrochanteric muscles pull the femoral head cranially and laterally. The psoas muscle plays a particularly important role for the luxated position of the femoral head as it becomes shorter, fits tightly to the anterior capsule and pulls the head out of the acetabulum thereby creating the so-called luxation path along which it continues to slide over the posterior acetabular rim until final luxation (6). The joint capsule twists around the longitudinal axis thereby creating a narrowing (isthmus capsulae) in the shape of a suglass. That is what often poses a big problem for repositioning the head into the acetabulum or completely prevents it, which in turn warrants a surgical treatment (7).

After the delivery, the luxated hip is released from mechanical factors and, for the most part, improvement takes place spontaneously. It may remain unstable and if instability persists, the hip becomes progressively irreducible. About half of the cases stabilise spontaneously and evolve into full recovery or into sequelae (subluxation or residual dysplasia) (8-11). In the other half, a timely clinical, ultrasound and, if necessary, radiographic diagnosis, with simultaneous DDH prevention or treatment, results in full recovery from DDH. Ultrasound enables a safe and secure visualisation as early as in the first days of life.

AIM

The aim is to establish, in a retrospective and prospective study, the prevalence of DDH in the first clinical and ultrasound examination in the period between January 1, 2006 and December 31, 2010.

MATERIAL AND METHODS

The examination is represented as a five-year retrospective and prospective study, covering the period between January 1, 2006 and December 31, 2010.

The examination included newborns that had their first clinical and sonographic examinations performed at the Traumatology Clinic of the Clinical Centre in Banja Luka. The patients were divided into groups based on sex, based on whether it was DDH affecting the right or left hip or whether it was bilateral, based on preventive therapy or treatment.

The personal medical record card of the patient includes clinical and ultrasound findings and it contains the following information: general information, such as name and surname, date of examination, date of birth, sex and address, family history of DDH - positive or negative. The risk factors relating to delivery are as follows: order of pregnancy, twin pregnancy, natural delivery (cephalic or breech), caesarean delivery (twin pregnancy, oligoamnios, malpositio in utero, vertebral column deformation, other flaws). Clinical risk factors are: limited abduction, Ortolani's sign, Palmen's sign, skin crease asymmetry, hip crepitations, lax hip, embryogenic hip luxation. The sonogram of the right and left hips contains the description of acetabular ossification, bony protrusion - acetabular labrum, cartilaginous part of the acetabulum, ossification nuclei, values of the alpha and beta angles and findings according to Graf (Types Ia, Ib, IIa+, IIa-, IIb, IIc, D, IIIa, IIIb, IV).

The Graf's method of ultrasound diagnostics with a LOGIQ 5 CE 0459 GE Medical Systems 2002 device was the diagnostic procedure used. Ultrasound characteristics and the Graf's hip type are recorded in the personal medical record card of the patient and hospital protocol, with the filmed findings containing measured angles and without angles, with a recommendation for a follow-up examination in case of ultrasound monitoring and a proposal for treatment in case of pathological findings.

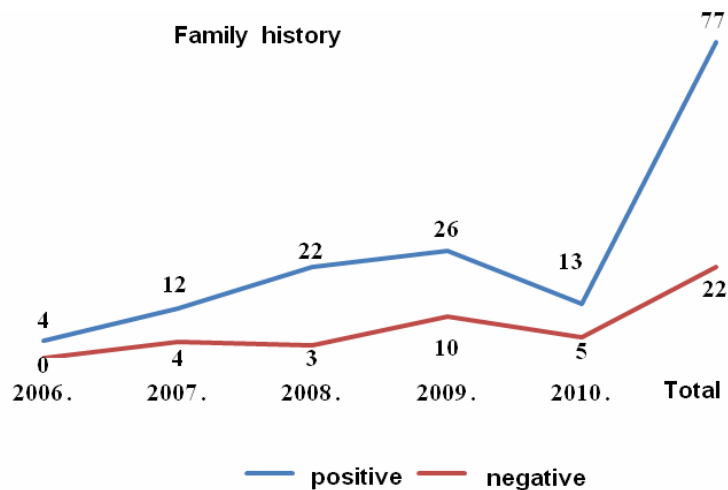
RESULTS

6132 newborns were examined in the five-year period, out of which number 2.965 were girls and 3.167 were boys, and the records were kept on an annual basis. 172 newborns were examined in 2006, 1072 in 2007, 1552 in 2008, 2125 in 2009 and 1211 in 2010 (Table 1).

The first sonographic examination in 2006 was performed 76 days after birth, while in 2010 it was performed 31 days after birth. The family history of the treated children was positive in 77.8% and negative in 22.2% of the cases (Graph 1).

Table 1. Examined patients by year

Year	Examined patients				
	Male		Female		Total
2006	78	45.35%	94	54.65%	172
2007	530	49.44%	542	50.56%	1072
2008	796	51.29%	756	48.71%	1552
2009	1162	54.68%	963	45.32%	2125
2010	601	49.63%	610	50.37%	1211
Total	3167	51.65%	2965	48.35%	6132

**Graph 1.** Family history by year of examination

In the examined sample, the firstborn children had DDH in the first clinical and sonographic examinations in 43.4% of the cases, the second-born children in 39.4%, the third-born children in 14.1% of the cases and in the fourth pregnancy there was DDH prevalence in 3.0 % of the cases. The most common delivery was natural, cephalic in 61.6% and breech in 17.2% of the cases, and by caesarean section in 19.2% of the cases. Twin pregnancies made up 2.0% of the cases. The risk factors in caesarean deliveries were predominantly malpositions in utero, in 78.6% of the cases, oligoamnios, in 17.9% of the cases, and in 3.6% of the cases these were deformations of the pregnant woman's vertebral column.

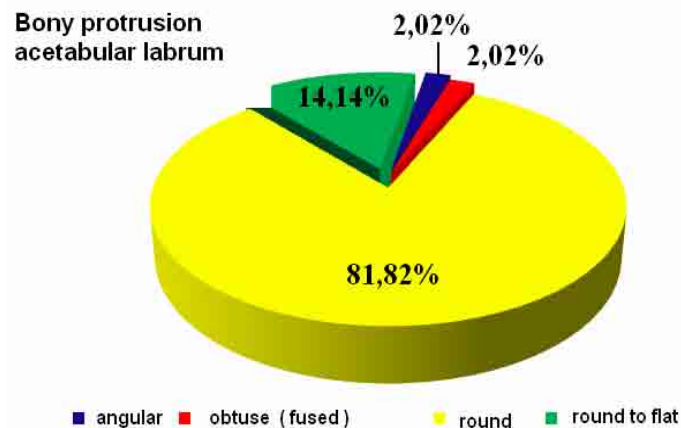
Limited abduction in the right hip was diagnosed in 12.1% of the newborns in the first clinical examination, while abduction in the left hip was limited in 96.0% of the cases. Ortolani's sign was positive in the right hip in 3%, and in the left hip in 33.3% of the patients. 3% of the newborns had a positive Palmen's sign in the right hip in the first examination, and 42.4% in the left.

3% of the patients had skin crease asymmetry on the right upper leg and 87.9% in the left. 46.5% of the patients had crepitations in the right hip and 83.8% in the left. 2% of the patients had a lax right hip, while 3% had a lax left hip. In 2008, in the first examination, we diagnosed 1 (1.0%) patient in the examined sample with embryogenic luxation in the right hip and 7 (7.1%) with embryogenic luxation in the left hip.

In the examined sample, the results obtained by the ultrasound of the ossified acetabulum of the right hip were as follows: good in 91.9%, satisfactory in 5.1%, insufficient (deficient) in 2.0%, and bad in 1.0% of the cases. The results obtained by the ultrasound of the left ossified acetabulum were as follows: good in 3.0%, satisfactory in 44.4%, insufficient (deficient) in 45.5%, and bad in 7.1% of the cases.

In the first sonographic examination, the bony protrusion - acetabular labrum on the right hip was angular in 90.9%, obtuse (fused) in 1.0%, round in 7.1%, round to flat and flat in 1.0%. In the sonographic examination, the bony protrusion - acetabular labrum on the left hip

was angular in 2.0 %, obtuse (fused) in 2.0%, round in 81.8%, round to flat and flat in 14.1% (Graph 2).



Graph 2. Presentation of bony protrusion /acetabular labrum/ of the left hip

In the examined sample, the cartilaginous part of the acetabulum of the right hip was:

- narrow and long, encompassed the femoral head (reduced angle β) in 4.0% of the cases;
- wide and short, slightly covered the femoral head (increases angle β) in 87.9% of the cases;
- the larger section of the bony part, encompassed the head and kept it in the acetabulum in 7.1% of the cases;
- pushed laterally (increases angle β by more than 77°) in 1.0% of the cases.

In the examined sample, the cartilaginous part of the acetabulum of the left hip was:

- wide and short, slightly covered the femoral head (increased angle β) in 4.0% of the cases;
- the larger section of the bony part, encompassed the head and kept it in the acetabulum in 88.9% of the cases;
- pushed laterally (increases angle β by more than 77°) in 7.1% of the cases.

The mean value of angle β on the right was 59.68° and on the left 54.08° , with an increase in angle β of 57.23° and 62.34° on the left, which corresponded to the bad clinical finding for the left hip. The ossification nuclei were present in 2% of the cases in the first sonographic examination.

In the first sonographic examination, the right hip findings according to Graf were as follows: Ia in 2%, Ib in 89.9%, Ila+ in 5.1%, Ila- in 2%, and D in 1% of the cases. In the first sonographic examination, the left hip findings according to Graf were as follows: Ib in 3%, Ila+ in 44.4%, Ila- in 24.2%, Ilb in 11.1%, Ilc in 10.1% and D in 7.1% of the cases.

After the first clinical and ultrasound examinations, 58.6% of the children required prophylactic measures (abduction swaddling and exercise), and 41.4% of the children required treatment instead. 6.132 children

were examined and 99 of them received treatment: 95 girls and 4 boys. The youngest treated female child was 28 and the oldest 150 days old. The youngest treated male child was 31 and the oldest 35 days old. After the first examination, treatment commenced using abduction pants in 52.5% of the cases, the Pavlik harness in 41.4%, and a plaster cast in the squatting position in 6.1% of the cases. As for the need for treatment following the first examination classified by gender, males made up 4% of the total number of treated children, while females made up 96%. Follow-up examinations were scheduled in two weeks in 32.3% and in four weeks in 67.7% of the cases.

DISCUSSION

It is important to commence with diagnosing and treating DDH as early as possible by applying atraumatic aids and procedures while all structures are elastic, reducible and adaptable (12). The prevalence differs by continent (ranging from 2 to 50 and more per 1000 births), and there are differences within regions of the same country. It is related to ethnic affiliation as well. DDH is unknown among the Bantu, and it is a very common condition among the aboriginal Canadians (12.3%) due to traditional swaddling (11, 13).

The lowest incidence is in Hong Kong, 0.01%, then in Northern Ireland, 0.14%, Sweden 0.17%, America 0.2-0.4%, Great Britain, about 1.5% (7, 9, 10). The DDH incidence in Serbia in the last decade has been around 2%. In 2002 and 2003, 4016 newborns were examined by ultrasound at the Neonatal Unit of the Gynaecology and Obstetrics Clinic in Novi Sad and at the Banjica Institute for Orthopaedic Surgery in Belgrade, and the DDH incidence established amounted to 1.95% (14, 15).

In Croatia, screening results show that DDH incidence is around 2%, although there are regions

where it is as low as 0.2%, but also as high as 4% (4). According to the latest information, the DDH incidence in Bosnia and Herzegovina is among the highest in Europe and it ranges from 3.2 to 6% (16).

The prevailing mode of delivery in the examined sample was natural: 61 (61.6%) were born head first and 17 (17.2%) bottom or feet first, while 19 (19.2%) were delivered by caesarean section. That number is large given the fact that the World Health Organisation recommends that maximum 10-15% of deliveries be performed by caesarean section. There has been a rise in this percentage in other countries too. In France, it amounted to 10% in 1981 and to 20% in 2004 (17, 19).

In 538 out of the 6.132 examined children clinical tests were positive predominantly for the left hip, which in turn amounts to 8.87-percent incidence diagnosed clinically. Maxwell mentions that the incidence based on clinical examination amounts to 1.66% (17), while Alečković, Brecej and Šoć state, based on the research in Donja Zeta, that it amounts to as much as 40% (20). Barlow mentions a very low DDH incidence that is based on clinical examination. He examined children at birth and then when they turned 4 months and he came to the conclusion that 60% of the hips that were unstable at birth stabilised in the first week, and 88% in the next two months. Around 12% had residual instability.

The given data suggests that performing a clinical examination is an insufficient and unreliable method of screening for DDH, but it needs to be performed as part of the examination of a child's hips (17).

The ultrasound examination was performed on all babies with an electronic 5-12-MHz probe using the standard Graf method. In addition to a standard screening, a four-phase sonographic screening (Harcke-Graf-Clarke) was performed on 12 (12.1%) babies.

In 2009, Kosar P. *et al.* in Ankara worked on a study involving 3400 infants and compared the standard (morphometric) and dynamic methods (Graf and Harcke methods) and established that 81.47% had Type I, normal hips, according to Graf and 91.48% had stable hips according to Harcke. The dynamic test (Harcke) was not performed on Type IIb and worse hips and that is why discrepancies are possible in terms of the percentage of normal and stable hips (20).

A study including 536 patients with clinical signs of hip instability was conducted at the University Hospital in Stockholm. Hip stability was assessed clinically and by ultrasound. The dynamic (Harcke) and Graf procedures were used for the ultrasound assessment. There were three groups created according to the Graf's method: 1. normal hips (Ia and Ib), 2. immature (borderline) hips (IIa), and 3. pathological hips (IIc and worse). According to the Graf's method, 77% of the hips were normal, 20% borderline, and 3% were pathological. The dynamic ultrasound showed that 88% of the hips were stable, 10% unstable, and 2% were disloca-

ted. The clinical examination showed that 82% of the hips were stable, 14% unstable and 4% were dislocated. Around 21% of the normal hips (Type I) according to Graf were unstable according to the dynamic test. The Graf's method showed the smallest number of normal and pathological hips, and the largest number of hips that needed follow-up (19).

A study conducted at the Health Centre in Solin, where 454 children were examined, obtained similar results. They performed ultrasound diagnosis using the Graf's method. In this research, 91.4% of the hips were found to be normal, 4.3% were Type IIa+, 1.5% were Type IIa-, 1.5% were Type IIc, 0.2% were Type IIIa, and 0.1% were Type IIIb (20).

When DDH was diagnosed within six weeks, its treatment was completed within the following month. And in one case, when the hip was classified in the third month, the treatment lasted until the child turned 2.5 years. Most authors believe that for the success of the treatment it is important to make a diagnosis and commence with the treatment within the first five weeks of life. After that period the treatment lasts longer, and the probability of surgical treatment is higher. Surgical treatment is recommended after six months (R. Graf) (35) or a year of treatment (6, 11). 'Diagnosis and treatment should start at the maternity unit', R. Graf (21).

CONCLUSION

In the examined sample, DDH was, in most cases, unilateral, predominantly in the left hip, and in firstborn babies (43.4%). Limited abduction in 96% of the examined children, positive Palmen's test in 42.4%, Ortolani's test in 33.3% and skin crease asymmetry in 87.9% were positive clinical signs present during the first clinical examination of the newborns. In the first ultrasound examination, the mean value of the alpha angle for the right hip was 59.68° , while the mean value of the beta angle was 57.23° . In the first performed ultrasound examination, the mean value of the alpha and beta angles was 54.08° and 62.34° , respectively. The incidence of DDH diagnosed clinically was 8.87% and of DDH diagnosed by ultrasound 1.61%.

The clinical examination is unreliable in terms of diagnosis of DDH, but it is mandatory as a part of the full physical examination of a newborn baby.

References

- Petković L: Ultrazvučna dijagnostika razvojnog poremećaja kuka u novorođenačkom i odojčadskom uzrastu, DM Grafika Novi Sad, 2002.
- Catteral, A: What is congenital dislocation of the hip, J.Bone Joint Surg ., 1984; 66-B,: 469-71
- Kokavec M, Bialik V: Developmental dysplasia of the hip. Prevention and real incidence. Bratisl lek Listy. 2007;:108(6):251-4.
- Matasović Tihomil i saradnici : Ultrazvučna dijagnostika sustava za kretanje, Školska knjiga-Zagreb, 1988.
- Storer SK, Skaggs DL : Developmental dysplasia of the hip. Am Fam Physician. 2006 Oct; 15:74 (8): 1310-6. Rewiev.
- Pajić D: Ultrazvučna dijagnostika razvojnog poremećaja kuka. Stylos Novi Sad, 1999.
- Düppe H, Danielsson LG: Screening of neonatal instability and of developmental dislocation of the hip. A survey of 132, 601 living newborn infants between 1956 and 1999. J Bone Joint Surg Br.2002; Aug: 84(6):878-85. PMID:12211683
- Graf R. Clasification of the hip joint dysplasia by means of sonography. Arch Orth Trau Surg 1984;:, 102: 284-92.
- Peled Eli, Eidelman M Mark, Katzman Alexander, Bialik Viktor. Neonatal Incidence of Hip Dysplasia Ten Years of Experince. Department of Orthopedic Surgery, Rambam Health Care Campus, Haifa, Israel, My 5 2007.
- Sahin F, Aktürk A, Beyazova U, Cakir B, Bayunaga O, Tezcan S, Bölükbası S, Kanatlı U. Screening for developmental dysplasia of the hip: results of a 7-year follow-up study. Pediatr Int. 2004 Apr; 46(2):162-6. <http://dx.doi.org/10.1046/j.1442-200x.2004.01855.x> PMID:15056242
- Vukašinić Z. Oboljenja dečjeg kuka, Škola za dizajn, Beograd,1994.
- Gerscovich EO. (1997) A radiologist s guide to the imaging in the diagnosis and treatment of developmental dysplasia of the hip. Skeletal Radiol 1997; 26: 447-56. <http://dx.doi.org/10.1007/s002560050265> PMID:9297748
- Graf R. Fendamentals of sonografic diagnosis of infants hip dysplasia., J Pediatr. Orthop, 1984;:4:735-40. <http://dx.doi.org/10.1097/01241398-198411000-00015> PMID:6392336
- Graf R, Farkaš P, Lercher K, Tschauner C, Lojpur M. Priručnik iz sonografije kuka, Sonogram-dijagnoza-terapija, Stolzalpe, 2001.
- Graf R, Wilson B. Sonographu of the infant Hip and its Therapeutic Implications, Chapman-Hall, London, 1995.
- Klisić PJ. (1989): Congenital dislocation of the hip: a misleading term (Brief report). J Bone Joint Surg (Br) 1989; 71:136. PMID:2914985
- Maxwell SL, Ruiz AL, Lapin KJ, Cosgrove AP. Clinical screening for developmental dysplasia of the hip in Norten Ireland. BNJ.2002 Apr 27:324 (7344):1031-3.
- Morey S.cott Sharon. Clinical Practice Guideline : Early Detection of Developmental Dysplasia of the Hip, April 2000.
- Omergolı H. Koparal S.s (2001) The role of clinical examination and risk factors in the diagnosis of developmental dysplasia of the hip.Pediatr Clin North Am 2001; 43:829-905 (Pub Med)
- Grissom LE, Harcke HT. Ultrasonography and developmental dysplasia of the hip. Curent Ooption in Oorthop 1999; .11:66-73,1999.
- Graf R. Hip sonography Diagnosis and Management of Infant Hip Dysplasia Second Edition Springer - Verlag Berlin Heidelberg 2006.

VRIJEDNOST PRVOG PREGLEDA RAZVOJNOG POREMEĆAJA KUKA - NAŠA ISKUSTVA

Predrag Grubor¹, Milan Grubor², Marinko Domuzin¹, Ivan Golubović³

¹Klinika za traumatologiju, Klinički centar Banja Luka, Bosna i Hercegovina

²Medicinska škola Banja Luka, Bosna i Hercegovina

³Klinika za traumatologiju, Klinički centar Niš, Srbija

Sažetak

Razvojni poremećaj kuka (RPK) označava izraženu dislokaciju (lateralizaciju i kranijalizaciju) glave femura u odnosu na slabije razvijeni (hipoplastičan i strmiji) acetabulum.

Cilj rada bio je da se utvrdi ukupan broj i karakteristike RPK na prvom kliničkom i ultrazvučnom pregledu, u retrospektivno prospektivnoj studiji, rađenoj u vremenskom periodu od 01. 01. 2006. do 31. 12. 2010. godine kod novorođenčadi koja su pregledana na Traumatološkoj klinici KC Banja Luka.

Pregledano je 6132, a liječeno 99 djece. Djevojčice su bile u znatno većem procentu liječenih (96%). Rađen je ultrazvučni a potom klinički pregled. Kod svih beba urađen je UZV pregled elektronskom sondom od 5-12 MHz standardnom metodom po Grafu.

Pozitivna porodična anemneza na RPK utvrđena je kod 7.8% i najčešća je kod prvorotki. Klinička incidenca iznosila je 8.87%, a ultrazvučna 1.61%. Prvim kliničkim pregledom dijagnostikovana je ograničena abdukcija na desnom kuku kod 12,1% novorođenčeta, dok je na lijevom kuku ograničena abdukcija bila zastupljena u 96,0%. Ortolanijev znak bio je pozitivan na desnom kuku kod 3,0%, a na lijevom kuku kod 33,3% ispitanika. Pozitivan Palmen-ov znak na desnom kuku na prvom pregledu imalo je 3,0% novorođenčadi a na lijevom 42,4%. Asimetriju kožnih brazdi na desnoj natkoljenici imala su 3%, a na lijevoj natkoljenici 87,9% ispitanika. Krepitaciju u desnom kuku imalo je 46,5%, a u lijevom kuku 83,8% ispitanika. Labav kuk bio je zastupljen kod 2% ispitanika na desnom kuku, a na lijevom kuku kod 3% ispitanika. Dobijeni rezultati koštano - oblikovanog acetabuluma ispitivanog uzorka desnog kuka bili su: dobar u 91,9%, zadovoljavajući 5,1%, nedostantno (manjkavo) 2,0%, loše 1,0%. Rezultati lijevog koštano - oblikovanog acetabuluma bili su: dobar u 3,0%, zadovoljavajući 44,4%, nedostantno (manjkavo) 45,5%, loše 7,1%. Koštano izbočenje, erker, na desnom kuku bio je ugaon u 90,9%, zatupljen (stopljen) 1,0%, okrugao 7,1%, okrugao do zaravnjen i zaravnjenog izgleda 1,0%. Koštano izbočenje, erker, na lijevom kuku bio je ugaon u 2,0%, zatupljen (stopljen) 2,0%, okrugao 81,8%, okrugao do zaravnjen i zaravnjenog izgleda 14,1%.

Dijagnostiku i liječenje RPK važno je započeti što ranije primjenom atraumatskih pomagala i procedura u periodu kad su sve strukture elastične, reponibilne i adaptibilne.

Klinički pregled je nepouzdan za dijagnostiku RPK, ali je obavezan u sklopu ukupnog pregleda novorođenčeta.

Ključne riječi: razvojni poremećaj kuka, ultrazvuk