

Research article

From the Down to Modern Era: The History of the Nailing.

Luigi Meccariello(1), Michele Bisaccia(2), Auro Caraffa(2), Predrag Grubor(3), Olga Bisaccia(4), Valerio Pipola(5), Elizabeth Mary Barron(6), Raffaele Cioffi(1), Raffaele Pezzella(7), Enrizo Manzi(8), Cristina Ibáñez Vicente(2), Luigi Piscitelli(2), Gabriele Falzarano(1).

1. U.O.C. Orthopedics and Traumatology, Azienda Ospedaliera “Gaetano Rummo”, Benevento, Italy
2. Division of Orthopedics and Trauma Surgery, University of Perugia, S. Maria della Misericordia Hospital, Perugia, Italy.
3. Clinic of Traumatology, University Hospital Clinical Center Banja Luka, Bosnia and Herzegovina.
4. Department of Diagnostic Imaging, “Niguarda Ca’ Granda” Hospital, Milano Italy
5. Department of Medical and Surgical Sciences and Neuroscience, Section of Orthopedics and Traumatology, University of Bologna, Bologna, Italy.
6. School of Medicine, Central Michigan University, USA
7. Clinic Of Orthopedic and Traumatology, IInd University Of Naples, Naples, Italy.
8. U.O. Orthopedic and Traumatology, Tarquinia Hospital , Tarquinia (Viterbo), Italy.

Corresponding Author:

Luigi Meccariello, MD

U.O.C. Orthopedics and Traumatology, Department of Emergency Azienda Ospedaliera “Gaetano Rummo”,
Via dell’ Angelo 1, Benevento, Italy

E-mail: drlordmec@gmail.com

Phone: +393299419574

Fax: +390823713864



This work is licensed under a [Creative Commons Attribution 4.0 International License](https://creativecommons.org/licenses/by/4.0/).

Abstract

Over the twentieth century, the field of orthopedics underwent a remarkable development in terms of advances in techniques and material science therein paving the way osteosynthesis. Specifically, the development of intramedullary nailing greatly improved upon the existing medullary intramedullary osteosynthesis. Here, we describe the roles of the persons behind the realization of this technique

Key Words: History; Nailing, Nailing In The War; War Trauma; WWI; WII; Cold War; Modern Era.

It is hard to determine who was the first surgeon to perform intramedullary nailing and what material was used. What is certain is that this method was first designed for the treatment of nonunion, that is, the cure of difficult to heal fractures. At Paris Roux (1), in August 1833, Cloquet, Dupuytren, Cruvelhier, Berard and proposed a new method for their treatment: after performing resection of the stumps he obtained stability by placing one end in the medullary canal of ' other. This technique was called "enclavement" or pegging was considered a primitive model of intramedullary nailing. The Prussian Johann Friedrich Dieffenbach, military surgeon and director of the Surgical Clinic of Berlin in 1841, proposed performing this method through the bone over the fracture site and with a filling of the holes with ivory pegs. This operation was well received and often practiced by contemporaries. Subsequently, major advances in techniques and material science led to further development: William Morton (1819-1868) introduced the use sulfuric ether for anesthesia, Von ErsMarch (1823-1909) invented the coronary band and Roentgen discovered X-rays. It is believed that Heine of Kiel, Germany in 1875 was the first to ivory nails during osteosynthesis. And between 1875 and 1886, also Bardenheuer, Socin and Bruns began using ivory nails for the treatment of femoral shaft fractures. Following this, experimentations with different nail materials. For example, Theodorescus used wooden nails for forearm fractures (Fig.1), specifically oak as it resulted being the most solid and compact.

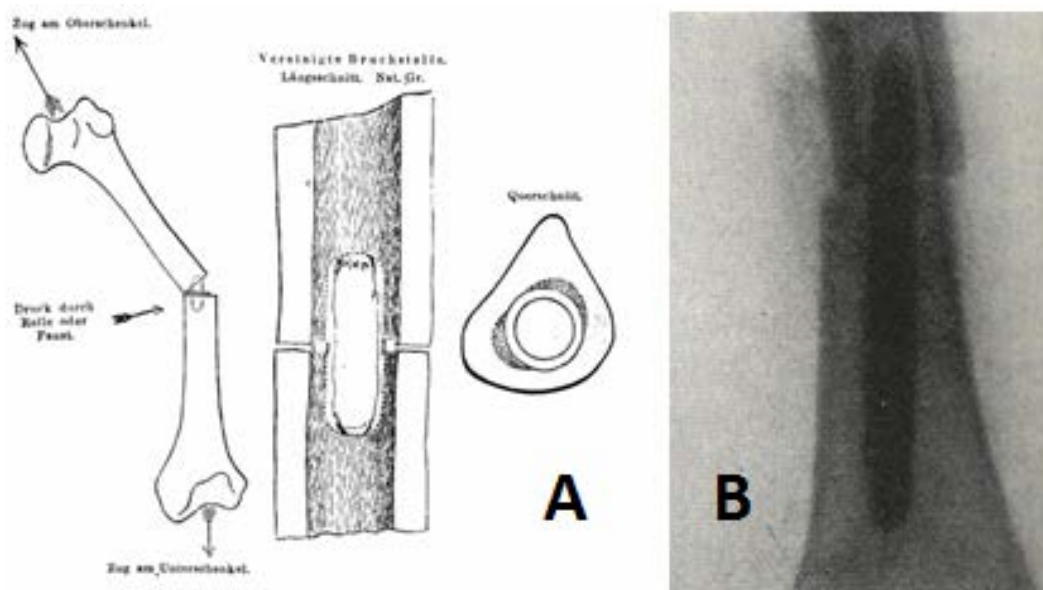


Fig.1: In Fig1.A the draws explain the surgical methods to reduction with Wood Nail of femoral shaft ; In Fig.1B, XR Shows Wood nail

Nicholas Senn (Fig.2), a Milwaukee military surgeon, experimented with ivory, cattle and metal bone for the treatment of femoral neck fractures in cats and later in humans. In Sweden in 1897, J. Nicolajsen introduced the principles of femoral neck nailing. In Belgium in 1907, Albin Lambotte was the first surgeon to place a nail intramedullary in a fractured collarbone. Four years later, in his "Chirurgie operatoire des fractures" Lambotte reports on the use of a nail "carpenter" for the synthesis of trochanteric femoral and metacarpal fractures. In the same year, Burgard in his "A system of operative surgery" describes the use of "knitting needles" for pertrochanteric synthesis. The needles were hammered into the bone, leaving one end to protrude out of the bone, in order to facilitate subsequent removal.

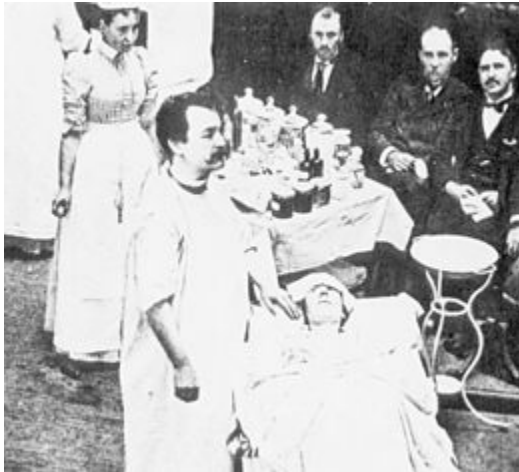

Fig.2: Nicholas Senn during surgery.

Nailing INTO WORLD WAR I

Another pioneer in the study of intramedullary fixation of the femoral shaft was the English military surgeon E. W. Hey Groves (Fig.3). In fact, during World War I, he treated 3 femoral fractures due to gunshot with steel nails (2). These nails were positioned in a retrograde after having rimmed the canal. The interventions were not deemed successful as the patients immediately died after the operation of septicemia.



Fig.3: E. W. Hey Groves

NAILING'S EVOLUTION BETWEEN THE TWO WARS


Dr. Smith Petersen (3) in 1925, introduced the "three-flanged" nail, which provided very good results regarding rotation control and a shorter time of restraint (from 4 to 2 weeks,); eliminating the use of a cast for the pelvis and ankle. In 1932, the Swede Sven Johansson proposed positioning a cannulated nail guided by a Kirschner wire. Following this, intra-articular surgery became extra-articular and was associated with lower rates of morbidity and mortality. This technique was also performed in Italy with excellent results (4): Guido Egidi, Primary Hospital Santo Spirito in Rome in his "Pinning subcutaneous fracture of the femur" of 1936 reported on 34 cases of neck fractures treated with "three-flanged" nailing.

Vittorio Putti (5) in 1938 at Rizzoli in Bologna devised a threaded nail with an impactor bolt fracture. Later, Codivilla (6) designed another nail for skeletal traction.

Americans Leslie V. Rush and H. Lowry Rush (7) worked with their father J. Rush Hack in Meridian, Mississippi. In 1937, they published a paper on the treatment of Monteggia fractures by axial fixation using a Steinman nail positioned antegrade olecranon. They claimed, that biomechanical forces exerted by muscles abductors on the proximal fragment of the femur were similar to those of the triceps on the olecranon fragment. The Rush nails became the most common method of osteosynthesis in North America. In London, in a report to the Royal Society in 1939, C. Lambrinudi reported three cases of stabilization of fractures synthesized with Kirschner wires. This method used a diaphyseal window at a distance from the fracture. This will have however been substituted thirty years later by Ender who introduced elastic nails.

WORLD WAR II AND KÜNTSCHER'S NAILS

Gerhard Kuntscher (Figure 4), was a German born military surgeon who revolutionized the treatment of fractures. He studied the properties of the callus and extensively investigated the behavior of long bones under load. Kuntscher was aware of the work of Pawels and Johansson on femoral neck fractures and became interested in the Müller-Meernach method which used intramedullary nails. The first intervention of shaft femoral nailing was performed in November 1939.



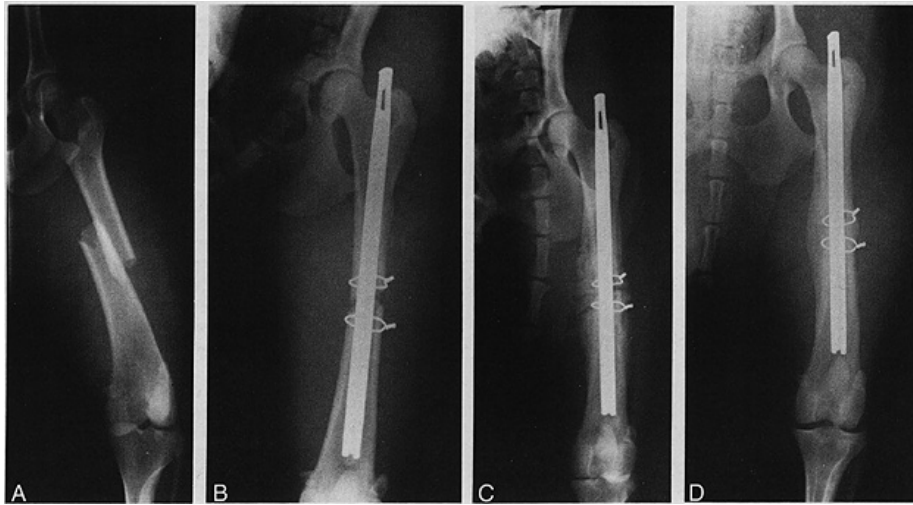


Fig.4: Kuntscher and his Nail...(A) Cranial-caudal radiograph demonstrates a transverse, mid-diaphyseal femoral fracture in a 1-year-old mixed breed dog. (B) Radiograph demonstrates the fracture following reduction and fixation using a Kuntscher nail and two wires. (C) Radiograph 6 weeks following fixation; (D) 12 weeks following fixation.

THE COLD WAR

At the end of World War II, research and development in the field of biochemistry and the engineering of materials flourished. In 1949 the United States began to produce stainless steel nails of both diamond and four-leaf clover-shapes. The following year these nails had already been implanted in 398 patients. Afterwards, J.O. Lottes developed a nail with a thread with an easy placement and removal. In Italy, the first shaft nailing with metal nail was executed by King Carlo in Turin in 1946. Whereas Francesco Delitala in 1950 at the Rizzoli Hospital in Bologna utilized some yarn with multiple hole a nail (9) which did not occupy the entire medullary canal exceeding the fracture site (Figure 5). The nail was positioned to take advantage of the socket with its holes and was introduced retrogradely. The nail was not locked and was a miss.

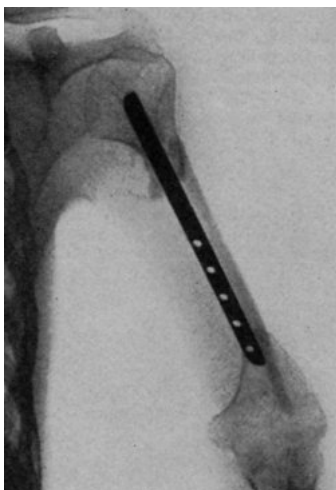


Fig.5

Domenico Vinditti at the end of the 1950s brought his coercing nail: the distal locking was performed through holes that had been filled with "thorns" metal. The device had a spring system to coerce? the trochanter

level. This distal locking system via fins would be subsequently incorporated into the Brooker Wills nail (11). Meanwhile in 1966, Kaessmann in collaboration with Weber realized a nail with a Kuntscher compression similar to that realized by Vinditti. The difference between the two was in the compression mechanism that was housed inside of the nail itself and therefore resulted being better tolerated by the patient.

In Italy, the use of nailing followed the Kuntscher method (12). In Switzerland, the AO group designed a procurvatum nail to better fill the femoral medullary canal following its normal physiological curve, which removed the proximal slit to have a greater resistance to twisting. From the 1960s, nailing was based on three mechanical conditions: first as suggested Lambotte, to stabilize the stumps of the fracture, second to fill the cavity and prevent shifting "to latus" when the nail is an open section cable that can interact with the tubular bone walls and third when the nail acts as a spring mechanism.

The major problem that required a solution was the smash: the shortening that followed it was a major limitation in the Kuntscher nail leading to the "detension" nail. Klaus Klemm (13) changed the direction of the proximal locking hole and with the approval of Kuntscher, defining it as a "blocked" nail. It was in the early 1970s that A. and I. Grosse Kempf in Strasbourg modified the nail locked to Klemm (14) by moving the inclination of the proximal locking screw from 150° to 130° to counteract its tendency to expulse. The nail was left cracked in the rear to maintain its elasticity. Meanwhile, Professor R. L. Huckstep (15) (16), had introduced a titanium nail square section equipped with a compressor to coerce the trochanter fractures sleepers. Huckstep argued that the square section and the quarry could preserve and favor the regeneration of bone marrow unlike nails having a cylindrical section which determined stress. Moreover, this nail could be utilized with ceramic rings to avoid significant bone substance loss, as in the case of fractures, pseudarthrosis, shortening and lengthening of limbs, tumors and arthrodesis. Ender in 1969 proposed the use of elastic nails for the treatment of fractures. These nails were full and supple and could be introduced by a shaft window far from the site of fracture. This technique had been utilized three decades earlier by Lambrinudi in England with the threads of Kirschnher. Robert Zickel from New York (17) in the same year proposed the use of stainless steel nails for the synthesis of trochanteric femoral fractures and later this method was utilized for the synthesis of distal femoral fractures. Zickel nails are made of elastic and curve forward, while in the cross section they are rectangular-shaped. Italians Gandolfi and Malavolta (18) expanded indications on the use of the Ender nails by mounting "Eiffel Tower" or intersecting arcs followed by plaster cast to treat shaft fractures of long bones using an elastic nail anchor. In the mid 1980s Andrew Brooker of Baltimore presented his blocked nail shortened by a transverse screw and distally by two molded fins delta protruding to the distal end of the nail activated by tightening a screw inside. Oscar Scaglietti, seeking to increase the number of contact points between the nails and the medullary canal, proposed "vibrant nails" (19). Likewise, during the same years, Russell-Taylor (20) developed a cable cross section with a four-leaf clover. Non-cracked it was positioned proximal with two holes having opposite inclinations to alternately favor the associated pertrochanteric screwing and diaphyseal fractures.

MODERN ERA

Italians Marchetti and Vicenzi (21) of the Rizzoli Hospital in Bologna created an elastic nail for femur, tibia and humerus fractures. The nail is introduced into the canal without boring and has one end which is locked with a screw while the other end has a bundle of pre-loaded nails that expand in metaphyseal cancellous epiphysis, activated by an extraction mechanism.

In the 1990s, the German Israeli fixation hydraulic expansion was introduced. The last time the system in order to be produced for the synthesis of long bones is the T2 system. This is a titanium nail with static locking with a dynamic controlled lock or coercing nail that can be placed antegrade or retrograde in the humerus of the femur (Fig.6). A similar device is available for the tibia. A similar device is present for the tibia. The evolution of pertrochanteric nail Kuntscher is represented by titanium Gamma 3 Nail (Fig.7) range proposed by G.Taglang in Strasbourg.

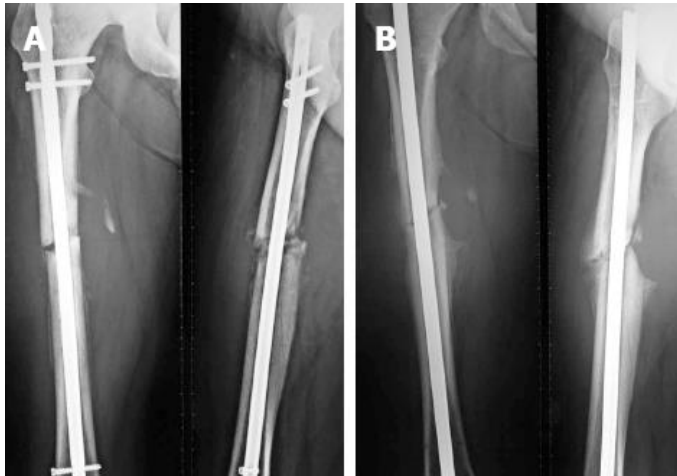

Fig.6 (Valli F, Teli MG, Innocenti M, Vercelli R, Prestamburgo D. Profunda femoris artery pseudoaneurysm following revision for femoral shaft fracture nonunion. World J Orthop. 2013 Jul 18;4(3):154-6. doi: 10.5312/wjo.v4.i3.154)

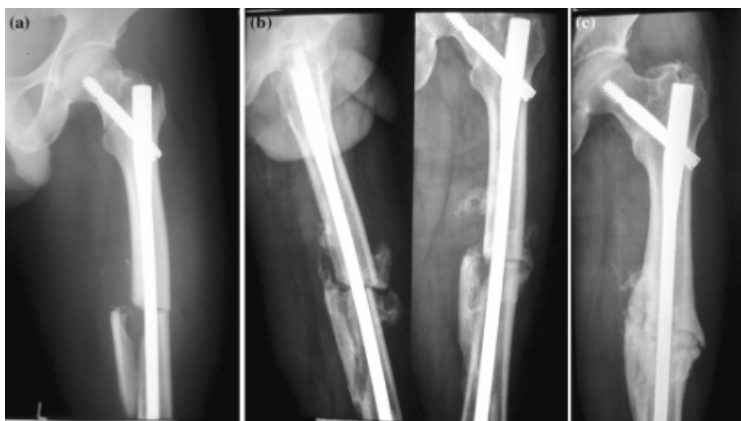

Fig.7 (Tsarouhas A, Hantes ME, Karachalios T, Bargiotas K, Malizos KN. Reconstruction nailing for ipsilateral femoral neck and shaft fractures.Strategies Trauma Limb Reconstr. 2011 Aug;6(2):69-75. doi: 10.1007/s11751-011-0117-0.)

CONCLUSIONS

Reviewing the history of nailing in osteosynthesis we have found that improvements in osteosynthesis technique pioneered by physicians worldwide were made possible by parallel advances in biochemistry engineering and material science.

"...the Care of fractures is the most important lesson of the war, clearly demonstrated in hospitals ..." Cit. Sir Reginald Watson Jones

ACKNOWLEDGMENTS

CONFLICT OF INTEREST STATEMENT: All authors disclose any financial and personal relationships with other people or organisations that could inappropriately influence (bias) their work. Examples of potential conflicts of interest include employment, consultancies, stock ownership, honoraria, paid expert testimony, patent applications/registrations, and grants or other funding.

References

- 1) Bircher H. Eine neue Methode unmittelbarer Retention bei Frakturen der Röhrenknochen. *Langenbecks Arch Chir.* 1886;34:410–22.
- 2) Hey Groves EW. Ununited fractures with special reference to gunshot injuries and the use of bone grafting. *Br J Surg.* 1918;5:185–242.
- 3) Marino Zuco C. Mezzi della moderna osteosintesi in traumatologia, XXXVI° Congresso SIOT, 1951.
- 4) Rotolo G: L'inciidamento percutaneo multiplo nelle fratture cervico-trocanteriche. *Arch. Ortop.*, vol. 66, 602, 1953.
- 5) Sinigaglia D : Inchiodamento percutaneo multiplo e temporaneo nelle -fratture del collo femorale. *Min. Ortop.*, vol. 7, 672, 1956.
- 6) Cabnera G : Sulle fratture pertrocanteriche del femore e loro trattamento. *Atti e Mem. S.O.T.I.M.I.*, vol. 7" (I), 19, 1962.
- 7) Rush LV, Rush HL. A technique of longitudinal pin fixation of certain fractures of the ulna and of the femur. *J Bone Joint Surg. Am.* 1939;21:619–26.
- 8) Danis R. *Théorie et Pratique de L'Ostéosynthèse.* Paris: Masson& Cie; 1949
- 9) Delitala Francesco: *scritti medici.* Pubblicati a cura del Comitato degli allievi in occasione del suo 90° anno di età. Bologna, Capelli Editore, 1973: XXXII-965.
- 10) Venditti D, Benini M. Proposta di un chiodo endomidollare «a pressione» o coartante. *Min Ortop.* 1962; 13: 368.
- 11) Brumback RJ(1), Reilly JP, Poka A, Lakatos RP, Bathon GH, Burgess AR. Intramedullary nailing of femoral shaft fractures. Part I: Decision-making errors with interlocking fixation. *J Bone Joint Surg Am* 1988 ; 70 (10): 1441 -1452
- 12) Gui L, Cuccioli U. Le fratture della diafisi del femore. Osteosintesi col metodo di Kuntscher. Bologna, A. Gaggi Editore, 1967: 35-8.
- 13) Browner BD, Wiss DA. The Grosse-Kempf locking nail for the femur. In: Browner BD, Edwards CC, editors. *The science and practice of intramedullary nailing.* Philadelphia: Lea & Febiger; 1987. p. 233–52.
- 14) Kempf I, Grosse A, Seidel H, Schvingt E, Taglang G, Campanacci M. L'enclouage centro-médullaire *Cahiers d'enseignement de la SOFCOT* 39, 1990.
- 15) Huckstep RL. The Huckstep intramedullary compression nail. Indications, technique, and results. *Clin Orthop Relat Res.* 1986;212:48-61.
- 16) Kim HK, Noh KC, Chung KJ, Hwang JH. Use of Huckstep nail in the periimplant femoral shaft fracture. *Indian J Orthop.* 2012 Nov;46(6):718-20.
- 17) Zickel RE. A new fixation device for subtrochanteric fractures of the femur: a preliminary report. *Clin Orthop Relat Res.* 1967;54:115-23.
- 18) Gandolfi M, Malavolta L, Tomasso A. Dynamic flexible intramedullary nailing in the treatment of fractures of the femoral diaphysis. *Ital J Orthop Traumatol.* 1986 ;12:159-66.
- 19) Scaglietti O, Marchetti PG, Bartolozzi P. I chiodi vibranti. *Arch Putti Chir Organi Mov.* 1985; 35:157-60.
- 20) Rudloff MI, Smith WR. Intramedullary nailing of the femur: current concepts concerning reaming. *J Orthop Trauma.* 2009 May-Jun;23(5 Suppl):S12-7.
- 21) Innovative Design Methods- Cap 3. Design of a new intramedullary tibial nail. Ingrassia T, Mancuso A, Ricotta V. In *The IM Pro Ve International Conference of Gianmaria Concheri, Roberto Meneghello, Giampaolo Savio*; ed. 2011; Libreria Internazionale Cortina Padova, Italy.