




Contents lists available at ScienceDirect

Injury

journal homepage: www.elsevier.com/locate/Injury

Does routine carpal tunnel release during fixation of distal radius fractures improve outcomes?

Antonio Medici^a, Luigi Meccariello^{b,*}, Giuseppe Rollo^b, Giancarlo De Nigris^a, Steven James McCabe^c,
Pedrag Grubor^d, Gabriele Falzarano^a

^aDepartment of Orthopedics and Traumatology, Gaetano Rummo Hospital, Benevento, Italy

^bDepartment of Orthopedics and Traumatology, Vito Fazzi Hospital, Lecce, Italy

^cHand Program, University of Toronto, Canada

^dOrthopedics and Traumatology, Clinical Center University of Banja Luka, Banja Luka, Bosnia and Herzegovina

KEY WORDS

Carpal tunnel syndrome
Carpal tunnel release
Not carpal tunnel release
Distal radius fractures
ORIF

ABSTRACT

Objective: This case–control study was designed to test the hypothesis whether carpal tunnel release (CTR) during fixation of distal radius 23–C2 AO fractures improves outcomes.

Methods: Thirty-five consecutive patients who sustained distal radius fractures of the dominant hand participated in this study. Patients were allocated into two groups: (a) The ORIF + CTR (16 patients (11 males and 5 females)); (b) the ORIF and NOT CTR 19 patients (12 males and 7 females). Patient assessment included visual analogic scale of pain (VAS), the subjective Mayo Wrist Score (MWS), electromyograms (EMG) at 3 month and 6 months from the day of injury and complications. All patients had the same physiotherapy treatment algorithm following surgery. Patient follow up took place at 1 month, 3, 6, and 12 months.

Results: At the T12 month follow up point the VAS average was 0.8 (range 0–3) in ORIF + CTR group compared to 1.2 (range 0–3) in the ORIF and NOT CTR. The MWS average was 98.7 (range 95–100) in ORIF + CTR group versus 97.6 (range 95–100) in ORIF no CTR group. There was no statistical significance ($p > 0.5$) between the two groups during the follow up period. Patients in the sixth month of ORIF + CTR had no suffering of the median nerve, while 31.58% of patients in ORIF and no CTR found to have carpal tunnel syndrome.

Conclusions: Routine release of the transverse carpal ligament at the time of fracture fixation may reduce the incidence of postoperative median nerve dysfunction.

© 2017 Elsevier Ltd. All rights reserved.

Introduction

Metaphyseal and intra articular distal radius fractures may cause symptomatic median nerve dysfunction through compression of the median nerve by volar displaced fragments, an increase in intracompartmental pressure secondary to post-traumatic edema, direct injury from fragment displacement causing contusion of the median nerve, hemorrhage, or a combination of any of these conditions [1]. The percentage of fracture fragment translation can be considered one of the most important risk factors for developing acute median nerve symptoms in patients with distal radius fractures and subsequent open reduction internal fixation (ORIF) [2]. The reported incidence of

median nerve neuropathy associated with distal radius fractures varies greatly in the literature ranging from 0.5% to 21% [1]. This case–control study was designed to test the hypothesis that patients who suffered 23–C2 AO fractures would have a better outcome with carpal tunnel release (CTR) during fracture fixation compare to patients that do not undergo CTR release.

Materials and methods

This study was conducted from January 2010 to December 2014 at the Department of Orthopedics and Traumatology, Gaetano Rummo in Benevento, Italy. 35 consecutive patients who sustained distal radius fractures 23–C2 AO classification of the dominant wrist were invited to participate. Patients were divided in two groups: a group with ORIF and CTR at the time of surgery whereas the other Group of patients underwent ORIF without CTR (Table 1). The decision to decompress or not the carpal tunnel was taken by the surgeon. Fixation of the fractures in all patients was carried out with plates and wires utilizing

* Corresponding author at: Department of Orthopedics and Traumatology, Vito Fazzi Hospital, Via Ada Cudazzo, Block: A-Floor: V, Lecce, Italy. Tel: +393299419574; Fax: +390823713864.

E-mail address: drlordmec@gmail.com (L. Meccariello)

Table 1
Description of population.

Description of population	ORIF + CTR	ORIF NOT CTR
Numbers of Patients	16	19
Average Age of Patients	30.4	28.3
Range of Age of Patient	18–55	18–55
Gender Ratio (M:F)	2.2 (11:5)	1.71(12:7)
Miscellaneous comorbidities: Numbers (%)	Kidney: 1 (6.25%) Diabetes: 2 (12.50%) Thyroid: 1 (6.25%)	Kidney: 0 (0%) Diabetes: 2 (10.53%) Thyroid: 2 (10.53%)
Upper Limb Tunnel Syndrome	Guyon's canal syndrome: 1 (6.25%) Cubital Tunnel syndrome: 2 (12.50%) Radial Tunnel Syndrome: 0 (0%)	Guyon's canal syndrome: 1 (5.26%) Cubital Tunnel syndrome: 1 (5.26%) Radial Tunnel Syndrome: 1 (5.26%)
Work of Population: Number (%)	Agricultural Activity: 5 (31.25%) Industrial Sector: 9 (56.25%) Tertiary Industry: 2 (12.50%)	Agricultural Activity: 6 (31.58%) Industrial Sector: 10 (52.63%) Tertiary Industry: 3 (15.79%)
Type of Accident: Number (%)	Fall From Height: 4 (25%) Car Accident: 3 (18.75%) Motorbike Accident: 4 (25%) Sport Accident: 2 (12.5%) Agriculture Accident: 3 (18.75%)	Fall From Height: 2 (10.53%) Car Accident: 6 (31.58%) Motorbike Accident: 5 (26.31%) Sport Accident: 5 (26.31%) Agriculture Accident: 1 (5.27%)
Type of Fractures According AO Classification: Number (%)	23-C2	23-C2

the anterior Henry approach to the wrist. Following informed consent, patients were allocated to either one of the two groups and were treated according to the Helsinki Declaration of ethical standards.

The ORIF + CTR group was composed of 16 patients (11 males) while the ORIF NOT CTR group was composed of 19 patients (12 male), (Table 1).

The average patient age in ORIF + CTR group was 30.4 years (range 18–55) compared to 28.3 in ORIF NOT CTR group (range 18–55), (Table 1). Comorbidities in ORIF + CTR group included: renal failure $n = 1$ (6.25%).

Diabetes $n = 2$ (12.50%), Thyroid metabolism diseases $n = 1$ (6.25%). Comorbidities in ORIF NOT CTR group included: renal failure $n = 0$ (0%); Diabetes $n = 2$ (10.53%); Thyroid metabolism diseases $n = 2$ (10.53%).

In ORIF + CTR group clinical signs of peripheral nerve syndromes prior to trauma were: Guyon's canal syndrome $n = 1$ (6.25%), Cubital Tunnel syndrome $n = 2$ (12.50%), Radial Tunnel Syndrome $n = 0$ (0%). In the ORIF NOT CTR group the following were noted: Guyon's canal syndrome $n = 1$ (5.26%), Cubital Tunnel syndrome $n = 1$ (5.26%), Radial Tunnel Syndrome $n = 1$ (5.26%).

Before trauma, in ORIF + CTR group patients' occupations consisted of agricultural activity $n = 5$ (31.25%), industrial sector $n = 9$ (56.25%), and tertiary industry $n = 2$ (12.50%), (Table 1). In the ORIF NOT CTR group patients' occupations consisted of agricultural activity $n = 6$ (31.58%), industrial sector $n = 10$ (52.63%), and tertiary industry $n = 3$ (15.79%), (Table 1).

In the ORIF + CTR group mechanism of injury included fall from a height $n = 4$ (25%); car accident $n = 3$ (18.75%); motorbike accident $n = 4$ (25%); sport accident $n = 2$ (12.5%); agriculture accident $n = 3$ (18.75%), (Table 1). In the ORIF NOT CTR group the following mechanism of accidents were documented: fall from height $n = 2$ (10.53%); car accident $n = 6$ (31.58%); motorbike accident $n = 5$ (26.31%); sport accident $n = 5$ (26.31%); agriculture accident $n = 1$ (5.27%), (Table 1).

All patients had initially standard AP and lateral radiographs and CT scans with 3D reconstructions. None of the patients had sustained other associated injuries. All patients underwent closed manipulation initially to improve fracture position and application of a back slab. Surgery was carried out with regional block anesthesia.

After surgery all wrists were immobilized with a volar splint for about 3 weeks, and active and passive finger motion exercises were started on the second postoperative day. An early active motion of the wrist was undertaken from about the 3rd postoperative week. The criteria chosen for the evaluation between the two groups were: visual analogic scale of pain (VAS), the subjective Mayo Wrist Score (MWS),

Electromyograms (EMG) and perioperative and postoperative complications.

The follow-up visits in the outpatient clinic were carried out at 1 month, 3 months, 6 months, 12 months. EMG studies were performed at 3 and 6 months.

Patients were excluded if they had pre-existing symptoms of carpal tunnel syndrome (CTS) or Median nerve symptoms after the trauma and previous treatment with CTR. The exclusion Criteria included alcohol or drug abuse, Rheumatoid Arthritis, relevant hematological pathologies, corticosteroid use, previous upper limb surgery, osteoporosis, and an age below 18 years or over 55 years. Patients that did not adhere to the assigned protocol and the 6-month follow up were also excluded. Data were imported in an electronic spreadsheet for further processing.

Statistical analysis

Descriptive statistics were used to summarize the characteristics of the study group and subgroups, including means and standard deviations of all continuous variables. The t test was used to compare continuous outcomes. The Chi-square test or Fisher (in subgroups smaller than 10 patients) exact test were used to compare Categorical variables. The statistical significance was defined as $p < 0.05$.

Results

Operation details between the two groups in terms of average days from trauma to surgery, duration of surgery, length of cast immobilization, length of surgical scar, and time to union is shown in Table 2.

Table 3 demonstrates the trend of wrist pain assessed with VAS pain score during the 12 months of follow up between the two groups of patients. There was not statistical significance ($p > 0.5$) between the two groups.

Before the trauma both group had excellent wrist's function measured with Mayo Wrist Score (MWS). At hospital admission the average MWS was 0 in both groups (Table 4). After surgery the average MWS was 15 in both groups (Table 4). At the First Month of follow up the average MWS was 3.4 (range 3–6) in ORIF + CTR group, while 3.4 (range 3–6) in ORIF NOT CTR (Table 4). The MWS score during the other follow up time points is shown in Table 4. There was not statistical significance ($p > 0.5$) between the two groups during the follow up.

With regards to assessment of the median nerve function with electromyography, at the 3 months time point in the ORIF + CTR group

Table 2
Surgical times and length of wound.

	ORIF + CTR	ORIF NOT CTR
Average Days from trauma to surgery	5.6	5.4
Range of Days from trauma to surgery	2–8	2–8
Average of length of surgery time (minutes)	63.2	52.1
Range of length surgery time (minutes)	43.2–110.4	30.4–111.3
Average Days cast used	21.9	20.4
Range cast used	20–24	18–25
Average of length wound in cm	9.5 cm	6.2
Range of length wound in cm	6.8–12.7	5.3–9.7
Average days for Bone Healing	30.4	30.3
Range days for Bone Healing	27–35	27–34

8 patients had a suffering of the median nerve with clinical symptoms, 50% of the total, while 12 patients 63.16% of ORIF NOT CTR group had a suffering of the median nerve with clinical symptoms. None of the patients in the sixth month of ORIF + CTR had suffering of the median nerve without clinical symptoms, while 31.58% of patients in ORIF NOT CTR had the carpal tunnel syndrome with clinical symptoms, all of these patients within a year from the trauma they had surgical CTR.

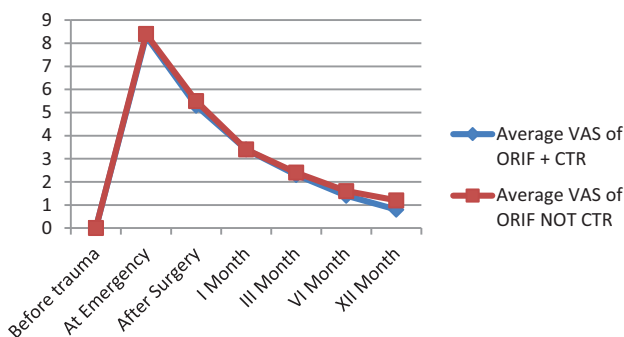
One complication was noted being breaking of the deep flexor of the first finger in a patient of the ORIF + CTR group after 14 months from the surgery.

Discussion

AO type C2 distal radius fractures are one of the most unstable fractures, and some authors have indicated the treatment with volar locking plate is the best choice of treatment [3–5]. While mechanical characteristics are important in fixation selection, the strategic placement of the selected materials may be more important than the characteristics of these materials, particularly in intra-articular fractures [8]. The advantages of open reduction and internal fixation include direct visualization and manipulation of the fracture fragments, stable rigid fixation, and the possibility of immediate postoperative motion. Fixed-angle plate designs minimize screw loosening in the distal fragments due to a “toggling effect” and thus reduce the danger of secondary displacement. The subchondral placement of smooth pegs is useful to buttress small articular fragments and successfully control shortening and angular displacement [9].

Table 3
Trend of wrist Pain measuring with VAS during the 12 months of follow up.

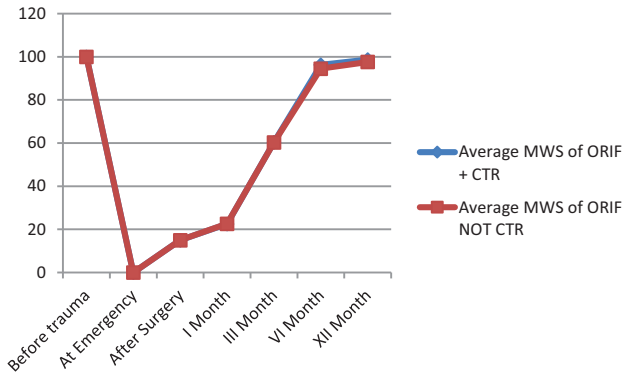
Time	Average VAS of ORIF + CTR	Average VAS of ORIF NOT CTR
Before trauma	0	0
At Emergency	8.3 (range 8–10)	8.4 (range 8–10)
After Surgery	5.3 (range 4–8)	5.5 (range 4–8)
I Month	3.4 (range 3–6)	3.4 (range 3–6)
III Month	2.3 (range 2–6)	2.4 (range 2–6)
VI Month	1.4 (range 1–4)	1.6 (range 1–4)
XII Month	0.8 (range 0–3)	1.2 (range 0–3)



There was not statistical significance ($p > 0.5$) between the two groups.

Table 4
Trend of wrist function measuring with Mayo Wrist Score during the 12 months of follow up.

Time	Average MWS of ORIF + CTR	Average MWS of ORIF NOT CTR
Before trauma	100	100
At Emergency	0	0
After Surgery	15	15
I Month	22.5 (range 20–25)	22.6 (range 20–25)
III Month	60.4 (range 55–65)	60.3 (range 55–65)
VI Month	96.3 (range 95–100)	94.5 (range 95–100)
XII Month	98.7 (range 95–100)	97.6 (range 95–100)



There were not statistical significance ($p > 0.5$) between the two groups.

Acute median nerve dysfunction is a well-known complication of distal radius fractures [1]. We have not observed cases of an acute median nerve dysfunction. There are different opinions regarding the decompression of the carpal tunnel with distal radius fracture ORIF. For patients with immediate median nerve symptoms and no progression of symptoms, they may be considered to have a median nerve contusion, which in some cases will resolve with observation [1,8]. At the time of injury to the wrist, there may be a combination of initial nerve contusion and carpal tunnel compression in cases of acute median nerve dysfunction with distal radius fractures and patients who have progression of symptoms, where urgent decompression may lead to improved results [9]. The aim of our study was purposely designed to identify patient reported outcomes that may be generalizable for common clinical practice. To reduce immediately the pain after the fracture, and the rate of complications regarding vascular, nerve and soft tissues of the wrist it is necessary to carry out a good manual reduction of the fracture [10]. In both groups we observed that there was no difference in the aesthetic judgment for patients in the length of the surgical wounds. In their studies on cadavers, Pensy et al. [11] have demonstrated the usefulness of Single-incision extensile volar approach to the distal radius and concurrent carpal tunnel release. However, the cost of treatment associated with open treatment are significantly higher than those with percutaneous fixation [12].

According to Niver and Iliays [13] a CTR is better managed after the complete healing of the distal radius fracture. There is no role for prophylactic carpal tunnel release at the time of distal radius fixation in a patient who is asymptomatic. However, at six months in the ORIF NOT CTR group we found the 31.56% patients with a positive electromyography Carpal Tunnel Syndrome. According to Cagle et al. [14] significant improvements in symptom severity and hand function may be expected after open carpal tunnel release in the general population regardless of age, medical comorbidities, or workers' compensation status. We had only one complication, the rupture of the deep flexor of the first finger in a patient ORIF + CTR group after 14 months from the surgery. The incidence of tendon ruptures after locked plating has been reported in the literature, even after palmar osteosynthesis due to oversized screws [15]. In most cases of volar

plating, tendon irritations seem to derive from technical errors and oversized screws [16,17–19].

In conclusion, distal radius fracture fixation and associated clinical outcomes continue to be topics of great clinical and scientific interest to the trauma community [18–25].

According to our data and the scientific literature [26–28] the volar plate osteosynthesis of C2 distal radius fractures in young patient with a concurrent prophylactic CTR can be safely performed as shown above in patients without signs or symptoms of acute CTS. Routine release of the transverse carpal ligament at the time of fracture fixation might reduce the incidence of postoperative median nerve dysfunction.

Limitations of the current study include the small number of patients, the lack of randomization, and the retrospective nature of the study. The non-significant results related to the differences between groups are probably due to a Type II statistical (small sample size). Finally, other limiting factors of the study acknowledged by the authors can be the presence of temporal confounders and the mention of subjective score.

Conflict of interest

All authors disclose any financial and personal relationships with other people or organizations that could inappropriately influence (bias) their work. Examples of potential conflicts of interest include employment, consultancies, stock ownership, honoraria, paid expert testimony, patent applications/registrations, and grants or other funding. None declared.

Human and animal right

Patients gave their informed consent prior to being included in the study. All procedures involving human participants were in accordance with the 1964 Helsinki declaration and its later amendments.

References

- [1] Chauhan A, Bowlin TC, Mih AD, Merrell GA. Patient-reported outcomes after acute carpal tunnel release in patients with distal radius open reduction internal fixation. *Hand* 2012;7:147–50.
- [2] Dyer G, Lozano-Calderon S, Gannon C, Baratz M, Ring D. Predictors of acute carpal tunnel syndrome associated with fracture of the distal radius. *J Hand Surg Am* 2008;33:1309–13.
- [3] Trumble TE, Schmitt SR, Vedder NB. Factors affecting functional outcome of displaced intra-articular distal radius fractures. *J Hand Surg Am* 1994;19:325–40.
- [4] Kamei S, Osada D, Tamai K, Kato N, Takai M, Kameda M, Nohara Y. Stability of volar locking plate systems for AOtype C3 fractures of the distal radius: biomechanical study in a cadaveric model. *J OrthopSci* 2010;15:357–64.
- [5] Orbay JL, Fernandez DL. Volar fixed-angle plate fixation for unstable distal radius fractures in the elderly patient. *J Hand Surg Am* 2004;29:96–102.
- [6] Gradl G, Gradl G, Wendt M, Mittlmeier T, Kundt G, Jupiter JB. Non-bridging external fixation employing multiplanar K-wires versus volar locked plating for dorsally displaced fractures of the distal radius. *Arch Orthop Trauma Surg* 2013;133:595–602.
- [7] Shukla R, Jain RK, Sharma NK, Kumar R. External fixation versus volar locking plate for displaced intra-articular distal radius fractures: a prospective randomized comparative study of the functional outcomes. *J Orthopaed Traumatol* 2014;15:265–70.
- [8] Szabo RM. Acute carpal tunnel syndrome. *Hand Clin*. 1998;14:419–29.
- [9] Bieniek T, Kusz D, Cielinski L. Peripheral nerve compression neuropathy after fractures of the distal radius. *J Hand Surg Br* 2006;31B:256–60.
- [10] Pretell Mazzini J, Beck N, Brewer J, Baldwin K, Sankar W, Flynn J. Distal metaphyseal radius fractures in children following closed reduction and casting: can loss of reduction be predicted? *Int Orthop* 2012;36:1435–40.
- [11] Pensey RA, Brunton LM, Parks BG, Higgins JP, Chhabra AB. Single-incision extensile volar approach to the distal radius and concurrent carpal tunnel release: cadaveric study. *J Hand Surg Am* 2010;35:217–22.
- [12] Farmer S, Malkani A, Lau E, Day J, Ochoa J, Ong K. Outcomes and cost of care for patients with distal radius fractures. *Orthopedics* 2014;37:e866–78.
- [13] Niver GE, Ilyas AM. Carpal tunnel syndrome after distal radius fracture. *OrthopClin North Am* 2012;43:521–7.
- [14] Cagle PJ Jr, Reams M, Agel J, Bohn D. An outcomes protocol for carpal tunnel release: a comparison of outcomes in patients with and without medical comorbidities. *J Hand Surg Am* 2014;39:2175–80.
- [15] Hakimi M, Jungbluth P, Windolf J, Wild M. Functional results and complications following locking palmar plating on the distal radius: a retrospective study. *J Hand SurgEur* 2010;35:283–8.
- [16] Tarallo L, Mugnai R, Zambianchi F, Adani R, Catani F. Volar plate fixation for the treatment of distal radius fractures: analysis of adverse events. *J Orthop Trauma* 2013;27:740–5.
- [17] Wichlas F, Haas NP, Disch A, Machó D, Tsitsilonis S. Complication rates and reduction potential of palmar versus dorsal locking plate osteosynthesis for the treatment of distal radius fractures. *J Orthop Traumatol* 2014;15:259–64, doi: 10.1007/s10195-014-0306-y.
- [18] Thorninger R, Madsen ML, Wæver D, Borris LC, Rölfing JHD. Complications of volar locking plating of distal radius fractures in 576 patients with 3.2 years follow-up. *Injury* 2017;48:1104–9.
- [19] Falk SS, Mittlmeier T, Gradl G. Results of geriatric distal radius fractures treated by intramedullary fixation. *Injury* 2016;47(Suppl 7):S31–5.
- [20] Gradl G, Falk S, Mittlmeier T, Wendt M, Mielsch N, Gradl G. Fixation of intra-articular fractures of the distal radius using intramedullary nailing: a randomized trial versus palmar locking plates. *Injury* 2016;47(Suppl 7):S25–30.
- [21] Solarino G, Vicenti G, Abate A, Carozzo M, Picca G, Colella A, Moretti B. Volar locking plate vs epibloc system for distal radius fractures in the elderly. *Injury* 2016;47(Suppl 4):S84–90.
- [22] Finger A, Teunis T, Hageman MG, Thornton ER, Neuhaus V, Ring D. Do patients prefer optional follow-up for simple upper extremity fractures: a pilot study. *Injury* 2016;47:2276–82.
- [23] Bockmann B, Budak C, Figiel J, Lechler P, Bliemel C, Debus F, Schwarting T, Oberkircher L, Frink M. Is there a benefit of proximal locking screws in osteoporotic distal radius fractures? A biomechanical study. *Injury* 2016;47:1631–5.
- [24] Bizzotto N, Tami I, Tami A, Spiegel A, Romani D, Corain M, Adani R, Magnan B. 3D Printed models of distal radius fractures. *Injury* 2016;47:976–8.
- [25] Lechler P, Börsch M, Timmesfeld N, Schwarting T, Boese CK, Frink M. The relationship between initial closed reduction and the surgical reconstruction of the radiocarpal joint line in distal radial fractures. *Injury* 2016;47:925–9.
- [26] Shukla R, Jain RK, Sharma NK, Kumar R. External fixation versus volar locking plate for displaced intra-articular distal radius fractures: a prospective randomized comparative study of the functional outcomes. *J Orthop Traumatol* 2014;15:265–70, doi: 10.1007/s10195-014-0317-8.
- [27] Bisaccia M, Rinonapoli G, Falzarano G, Medici A, Meccariello L, Rosati R, et al. Clinical and radiological outcomes of distal radius fractures treated with orif with volar plates. *EMBJ* 2016;11:9–14, doi: 10.3269/1970-5492.2016.11.02.
- [28] Thorninger R, Madsen ML, Wæver D, Borris LC, Rölfing JHD. Complications of volar locking plating of distal radius fractures in 576 patients with 3.2 years follow-up. *Injury* 2017;48:1104–9, doi: 10.1016/j.injury.2017.03.008.