

Selection Methods in the Treatment of Diaphyseal Tibial

Predrag Grubor^{1*}, Milan Grubor², Milan Mitković³ and Rade Tanjga²

¹Traumatology Clinic, Clinical Centre Banja Luka, Republika Srpska, Bosnia and Herzegovina

²Medical School, Banja Luka University, Bosnia and Herzegovina

³Traumatology Clinic, Clinical Centre Nis, Serbia

Received: December 04, 2013; Accepted: August 26, 2014, Published: September 10, 2014

*Corresponding author: Predrag Grubor, No. 20/24, Aleja Svetog Save, Banja Luka, Republika Srpska, Bosnia and Herzegovina, Tel: 00-387-65-513-115; E-mail: predraggrubor@gmail.com

Abstract

Introduction: Tibial fractures accompanied by radius fractures at typical sites are the most common type of fractures.

Objective: The study is aimed at using the examined sample to make an efficient and economically acceptable choice in the treatment of tibial fractures.

Material and methods: The series comprises a retrospective and prospective study of the treatment of 131 fresh tibial fractures: 31 in women (23.66%) and 100 in men (76.34%) of the average age of 37.89. Nineteen patients (14.50%) were treated conservatively and 112 (85.50%) surgically: 22 (16.79%) with anti-rotation intramedullary nails, 74 (56.49%) with Mitković external fixator type M20, and 16 (12.21%) with LCP. General anaesthesia was used in 46 patients (35.11%), while spinal anaesthesia was used in 85 of them (64.89%).

Results: According to the Karlstrom-Olerud scoring system, the treatment results were as follows: for the 22 tibiae treated with anti-rotation intramedullary nails: in 15 (68.18%) the results were excellent, in 3 (13.64%) they were good and in 4 (18.18%) they were poor. As for the results for the 74 tibiae treated with Mitković external fixator type M20, they were as follows: in 62 (83.78%) excellent, in 9 (12.16%) good, and in 3 (4.05%) they were poor. The results for the 16 patients treated with LCP were excellent in 10 (62.50%), good in 2 (12.50%) and poor in 4 patients (25.00%). The treatment results for the 19 tibiae treated with plaster cast were excellent in 12 patients (63.16%), good in 2 (10.53%) and poor in 5 (26.32%). The definite results for the 131 fractured tibiae treated with the aforementioned techniques were as follows: excellent in 99 (75.57%), good in 17 (12.98%) and poor in 15 patients (11.45%).

Discussion: There is a variety of controversial positions concerning the treatment of the tibial diaphysis.

Conclusion: On the basis of the results of surgical treatment for the given series, the number of surgical interventions, the price of osteosynthetic material, my preferences in treating tibial diaphyseal fractures would be as follows:

1. Mitković external fixator type M20,
2. anti-rotation intramedullary nails and
3. LCP.

Conservative treatment is indicated when the X-ray examination confirms that the fragments have a position acceptable for conservative treatment with plaster cast.

Introduction

Fractures of the lower leg or the tibia itself, accompanied by fractures of the radius at typical sites are the most common type of fractures [1]. They occur at any age, more frequently in young people. Fractures that are considered tibial diaphyseal fractures are those that occur between the knee and ankle joint. We distinguish fractures of the upper, medial and lower thirds of the tibia [2]. A fracture occurs through direct and indirect application of force. Direct fractures are usually transverse, slightly oblique or comminuted, while indirect ones are torsional - rotational fractures. A fracture can easily turn into an open one due to the direct contact of the tibia with the skin.

Tibial fractures come in different forms and sizes. Every fracture must be treated individually. When determining the treatment for the tibia, the following must be taken into account: localisation and type of fracture, condition of the soft tissue surrounding the fracture, general condition of the patient.

There are different non-surgical and surgical methods for treating tibial fractures. Non-surgical treatment means treatment with plaster cast immobilisation, extension. In addition to a good healing tendency, the advantages of conservative treatment lie in avoiding potential risks that come with surgical treatment, such as infections. Surgical treatment is the most common form of treatment nowadays [2,3]. External skeletal fixations, using a fixator [2], and internal fixation, using anti-rotation intramedullary nails and Locking Compression Plates (LCP) [3], are most frequently used to stabilise bone fragments of the tibial diaphysis.

Objective

The study is aimed at using the examined sample to make the most efficient medical and the most economical choice in the treatment of tibial fractures.

Material and Methods

The series comprises a retrospective and prospective study of the treatment of fresh tibial fractures in 131 patients, 31 women (23.66%) and 100 men (76.34%) of the average age of 37.89, treated at the Traumatology Clinic in Banja Luka in the period

between 1 March 2010 and 1 March 2013. Seventy-nine patients (60.31%) suffered a fracture of the right tibia and 52 (39.69%) of the left. Thirty-eight patients (29.01%) in the examined sample suffered a polytrauma. Thirty-one patients (23.66%) suffered a transverse fracture, 53 (40.46%) oblique, 32 (24.43%) spiral and 15 patients (11.45%) suffered a segmental/comminuted fracture. There were open fractures in 13 patients (9.92%). The following is the incidence of open tibial fractures: Gustilo Grade-I fractures in 7 (5.34%), Gustilo Grade-II in 5 (3.82%) and Gustilo Grade-III [4] in 1 patient (0.76%). All patients with open fractures were treated with Mitković external fixator type M20 (M20) [5].

The nineteen patients (14.50%) whose initial x-ray examinations confirmed that the fragments had an acceptable position for the treatment with plaster cast were treated conservatively. 19 spirale fractures of diaphysis of tibia were treated conservatively by plaster.

On average, the definitive plaster cast was placed on the sixth day, over the existing plaster cast, and a follow-up x-ray examination was performed. If the x-ray confirmed there was no dislocation of the fragment, the treatment continued at home, with a recommendation to walk with axillary crutches (non-weight bearing) in order to satisfy basic needs. The first follow-up was performed 15 days later, with the x-ray shot through the cast. Negative x-ray findings enable the patient to walk with axillary crutches, with up to 5 kg weight bearing. Follow-ups were performed every 15 days, including x-ray. After six weeks, the same plaster cast was shortened to below the knee, and the follow-up after four weeks was performed with an x-ray examination of the tibia without the plaster cast. Radiographic and clinical findings indicated the need for further treatment: without a plaster cast or with a functional plaster cast until full recovery.

One hundred and twelve tibiae (85.50%) were treated surgically: 74 with Mitković external fixator type M20 (56.49%) (Figure 1), 22 with anti-rotation intramedullary nails (16.79%), and 16 with LCP (12.21%).

General anaesthesia was used in 46 patients (35.11%), while spinal anaesthesia was used in 85 of them (64.89%).

We did not use a portable x-ray machine with a display to assist us in performing closed repositioning of fractures followed by stabilisation. We are of the opinion that a tissue trauma is greater in case of closed repositioning because the first attempt to reposition the fragments is rarely successful. Also, the risk of x-ray radiation is not insignificant for the surgical team. A semicircular anterolateral skin incision above the fracture and across the tibial muscle results in a minor soft tissue trauma facilitates safer repositioning and stabilisation of the fracture under direct visualisation. 61 closed fractures were treated by Mitkovic M20 external fixator. Those were fractures of diaphysis, short and long spirale fractures, transversal and fractures with big triangle free fragment, all of them with dislocation. External fixator Mitkovic M20 type was used at 13 casualties, of which: Gustilo I were 7 casualties, Gustilo II were 5 casualties, Gustilo III were 1 casualty.

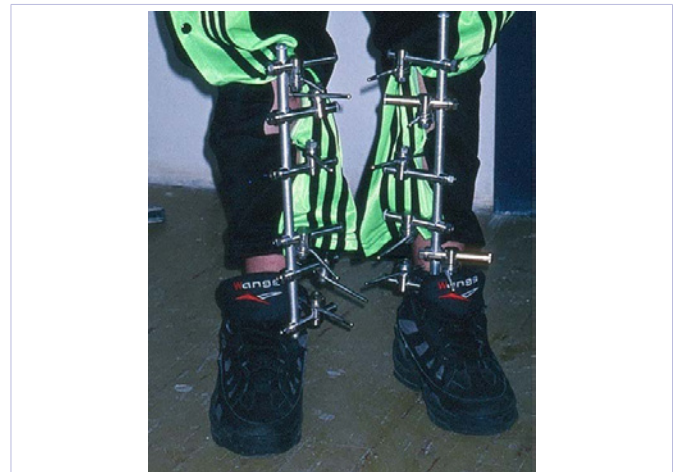

Figure 1: Clinical result three months after tibial fractures treated with Mitković external fixator type M20.

When we, after repositioning the bone fracture, placed an external fixator type M20, we used bone holders to maintain the temporary reposition, and we performed definitive stabilisation using the M20 [5]. The pins were inserted through approximately 1-cm long skin incisions, two above (anteroposteriorly and mediolaterally) and two below the fracture site. We used six pins for segmental and comminuted fractures. The pins for the external fixator type M20 were inserted at the incision sites. The clamps, holders and M20 frame were placed [5]. The bone holders were then removed, and the fracture stability drains and wound stitches by layers were checked.

Fixation by anti-rotation intramedullary nails was used at closed short transversal fractures as well as at fractures with big triangle fragment. All of these were fractures with long sanation. The method of work with anti-rotation intramedullary nails: we made semicircular skin incisions and repositioned the fracture which we then held with bone holders. We flexed the knee to 90° and verified the tibial tuberosity. We made a short skin incision above the patellar ligament, through which we approached the tibia using a reamer, making space to apply a locked intramedullary nail. The intramedullary nail was placed through the medullary canal and it kept the tibial fracture stabilised, and additional screws below and above the fracture stabilised it further. In addition to the infrapatellar incision used in order to place the locked intramedullary nail, the patients also had small incisions below the knee and above the ankle joint through which anti-rotation screws were inserted. The average length of the locked intramedullary nail was between 28 and 36 centimetres and the diameter was between 8 and 9 millimetres.

LCP fixation

It was placed subcutaneously following the repositioning. There was a need to make small skin incisions proximally and distally from the fracture in order to insert the screws. Spirale type fractures, short transversal, and fractures with big free fragment, all of them dislocated, were treated by LCP plate. The average time of surgery to place anti-rotation intramedullary nails amounted to approximately 86 minutes, with the help of two

surgical assistants. One assistant was needed to reposition and apply the external fixator type M20 in approximately 25 minutes. LCP fixation was performed with the help of one assistant and it took approximately 35 minutes.

All operated patients were mobilised on the first postoperative day, and the average length of inpatient stay was four days. For the patients whose fractures were treated conservatively, the length of inpatient stay amounted to an average of seven days.

All surgically treated patients received antibiotics for five days on average, and all patients received medicamentous thromboembolism prophylaxis.

Results

Out of the 22 tibial fractures treated with anti-rotation intramedullary nails, one patient (4.55%) had a deep infection and the intramedullary nail had to be removed. In 3 patients (13.64%) there was a diastasis at the fracture site and the bone union process was prolonged. We revitalised the fracture by removing the proximal screws, in order to facilitate fracture healing by dynamisation. In two of these three patients (9.09%) the treatment finished with pseudoarthrosis. As for the fractures in the proximal third of the tibia, 1 patient (4.44%) had an antecurvatum deformity and skin dehiscence. Three patients (13.64%) suffered transient contractures in the knee, and 7 (31.82%) suffered knee pain. Three patients (42.85%) suffered pain when kneeling and 4 (57.14%) when resting. This pain was accompanied by a hypertrophic infrapatellar scar. The average period for fracture healing was 17.2 weeks. On average, the locked intramedullary nail was removed 9.5 months after its placement, under general anaesthesia.

The criteria for assessing the treatment results were determined according to the modified Karlstrom-Olerud scoring system [6], which covers five subjective symptoms and seven objective signs [6]. According to this scoring system, the results of treatment with anti-rotation intramedullary nails in the series of 22 tibiae were as follows: in 15 patients (68.18%) they were excellent, in 3 (13.64%) good, and in 4 (18.18%) they were poor (Table 1).

The price of a locked intramedullary nail amounts to €480 and it is disposable.

Out of the 74 tibial fractures treated with a Mitković external fixator type M20, infection occurred in 16 nails. In 13 nails, infection healed due to adequate hygienic measures around the nails, and three nails were re-assembled. There was no deep infection or skin necrosis. In 3 patients (4.05%) the treatment resulted in pseudoarthrosis and one tibia was in a valgus position of approximately 8 degrees. There were no contractures, knee pain or pain in the ankle joint. The healing period for tibial fractures was 16.9 weeks. The fixator type M20 was removed without anaesthesia in the surgery after five months.

According to the Karlstrom-Olerud scoring system, the results for the treatment of the series of 74 tibia with Mitković's external fixators type M20 are as follows: 62 (83.78%) were excellent, 9 (12.16%) were good, and 3 (4.05%) were poor.

Table 1: Assessment of treatment results for intramedullary nails according to modified Karlstrom-Olerud scoring system.

Treatment results (anti - rotation intramedullary nails)	No. of patients	
	f	%
Excellent	15	68.18
Good	3	13.64
Poor	4	18.18
Total	22	100.00

The price of a Mitković external fixator type M20 is €950. It is re-usable in the treatment of tibial fractures.

Out of the 16 tibiae treated with LCP, 2 patients (12.50%) suffered a deep infection and the plate had to be removed. The treatment was continued using an external fixator. One patient suffered from skin necrosis, and two from transient dehiscence. The treatment resulted in pseudoarthrosis in 2 patients (12.20%). The average time needed for a fracture to heal was 18.2 weeks. On average, the plate was removed in the operating theatre after 10.2 months, under anaesthesia.

The results obtained according to the Karlstrom-Olerud scoring system for the treatment of the series of 16 tibiae with LCP are as follows: 10 (62.50%) were excellent, 2 (12.50%) were good and 4 (25.00%) were poor.

The price of a locking compression plate amounts to €750. It can be used on one patient and is disposable.

As for the 19 tibiae treated conservatively, thrombophlebitis occurred in 2 patients (10.53%), and 3 patients (15.79%) suffered dislocation of fragment(s) and their treatment continued surgically. There were 3 patients (15.79%) with CRPS Type II, and there was a valgus deformity greater than 5 degrees in 1 patient (5.26%). Three patients (15%) had knee and ankle joint contractures, and 1 patient (5.26%) had ankle joint pain. The mean time for fracture healing in a plaster cast amounted to 16.1 weeks.

According to the Karlstrom-Olerud scoring system, the results for the series of 19 tibiae treated with a plaster cast were as follows: 12 patients (63.16%) had excellent results, 2 (10.53%) had good, and 5 (26.32%) had poor results (Figure 2).

The price of a plaster cast for treating tibial fractures amounts to €25.

According to the Karlstrom-Olerud scoring system, the final treatment results for the series comprising 131 patients treated for tibial fractures with fixator type M20, locked intramedullary nail, LCP and plaster cast are as follows: excellent in 99 patients (75.57%), good in 17 (12.98%) and poor in 15 (11.45%).

The total treatment results for the patients in the examined sample, by type of surgical and conservative treatment, are shown in Figure 3.

By comparing research groups, the Mitković external fixator

type M20 seems to have an advantage compared to the anti-rotation intramedullary nail and LCP in terms of the number of surgical interventions. At the same time, the Mitković external fixator type M20 takes precedence over other treatment methods (anti-rotation intramedullary nail and LCP) in terms of its price, too. Although the price of the Mitković external fixator type M20 is the highest and it amounts to €950, the fact that the M20 can be used multiple times (in the author’s experience minimum five times, which in turn amounts to maximum €190 per treatment) shows that the application of the M20 is the most convenient, given the price of osteosynthetic material and possibilities for multiple use.

The results of the comparative analysis of the treatment results by type of surgery are given in Table 2-4.

The following values (results) were taken as the outcomes: duration of surgery (min), number of surgical assistants, mobilisation and weight-bearing time, average length of inpatient stay, average amount of spent blood (ml), complications, mean fracture healing time (weeks), price (€), treatment quality score.

Every outcome (result) is accompanied by a ranking, using the minimum (maximum) result criterion. The summed score of

individual rankings was calculated afterwards and the treatment quality score was calculated based on that (Figure 4).

The ranking for specific types of surgery was made on the basis of the summed score of individual rankings and it is as follows:

1. Mitković external fixator type M20,
2. Anti-rotation intramedullary nails,
3. LCP.

Discussion

Non-surgical treatment of tibial fractures with a functional plaster cast introduced by Sarmiento is still very popular, and it is widely applicable in everyday practice of orthopaedic trauma. However, treatment with a functional plaster cast was not the best solution for unstable fractures which lost their accomplished repositioning in the plaster cast and in turn resulted in non-union, shortening and unacceptable angulation [7].

Surgical treatment of tibial diaphyseal fractures usually leads to the union of fractures, with no consequences on the living potential and work capability [7]. The most commonly

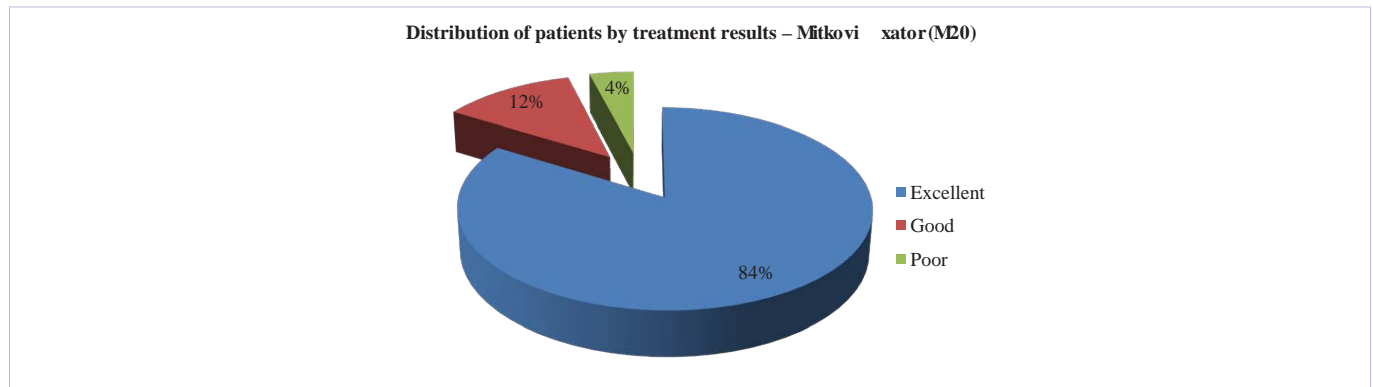


Figure 2: Assessment of treatment results for Mitković fixator type M20 according to modified Karlstrom-Olerud scoring system.

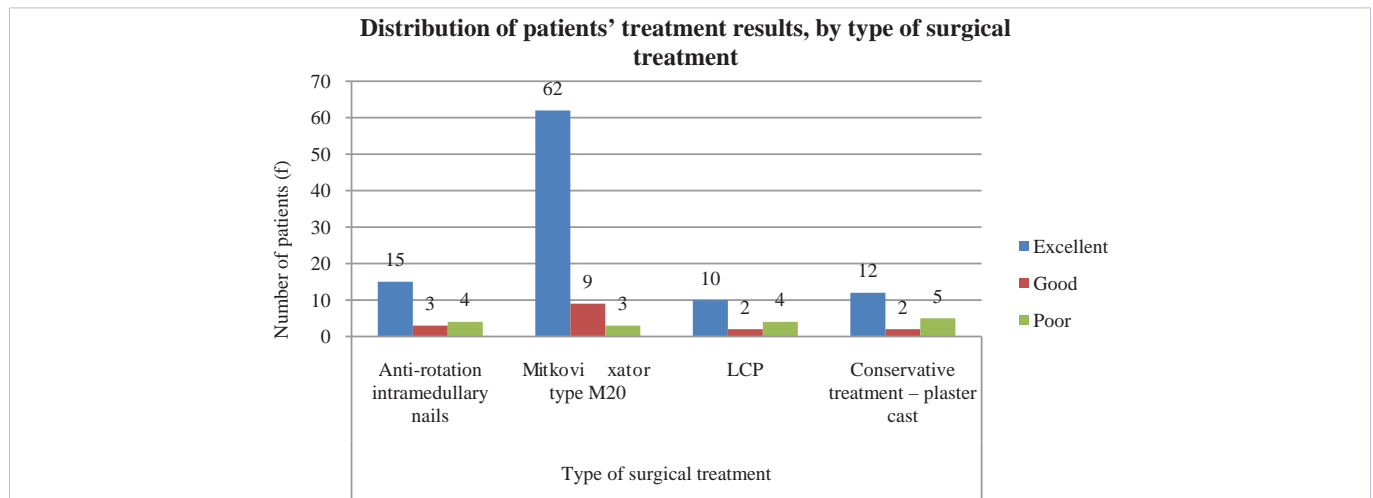


Figure 3: Assessment of results of complete treatment.

Table 2: Assessment of treatment results for LCP according to modified Karlstrom-Olerud scoring system.

Treatment results (LCP)	No. of patients	
	f	%
Excellent	10	62.50
Good	2	12.50
Poor	4	25.00
Total	16	100.00

Table 3: Assessment of results of conservative treatment with plaster cast according to modified Karlstrom-Olerud scoring system.

Conservative treatment results (plaster cast)	No. of patients	
	f	%
Excellent	12	63.16
Good	2	10.53
Poor	5	26.32
Total	19	100.00

: Comparative analysis of treatment results.

Type of surgery	Duration of surgery (min)		Number of surgical assistants		Mobilisation and weight-bearing time		Average length of inpatient stay		Average amount of spent blood (ml)		Complications		Mean fracture healing time (weeks)		Price (€)		Treatment quality score		Total ranking score	
	Ranking	Ranking	Ranking	Ranking	Ranking	Ranking	Ranking	Ranking	Ranking	Ranking	Ranking	Ranking	Ranking	Ranking	Ranking	Ranking	Ranking	Ranking	Ranking	Ranking
Anti-rotation intramedullary nail	86	3	2	2	1	1	4	1	320	2	4	2	17.2	2	480	2	2.50	2	17	2
Mitković fixator type M20	25	1	1	1	1	1	4	1	0	1	3	1	16.9	1	190	1	2.80	1	9	1
LCP	35	2	2	2	2	2	4	1	0	1	5	3	19.2	3	750	3	2.38	3	20	3

used operative methods for tibial diaphyseal fractures are intramedullary fixation (3), DCP fixation [6] and external skeletal fixation with different types of external skeletal fixators (Hoffmann, Ilizarov, AO, Orthofix) [8].

Out of the 44 closed tibial diaphyseal fractures and Gustilo Grade-I and Grade-II open fractures that Shaw *et al.* [9] treated with external skeletal fixation all fractures healed.

Keating *et al.* [10] had union in 95% of tibial diaphyseal fractures after treating 100 fractures (47 and 53 closed and open, respectively) with Orthofix external skeletal fixators. In the same series, the authors had 6% fracture non-unions, and fracture malunions in 14% of closed and 32% of open fractures.

Krettek *et al.* [11] had 10.9% fracture non-unions after external skeletal fixation of 202 tibial diaphyseal fractures (70 and 132 closed and open fractures, respectively).

Placing a Mitković external skeletal fixator takes a short time, there is no blood loss, there is minimum damage to bone

vascularisation, and post-operative length of inpatient stay is short [5,8].

Bone treatment may last between six and sixteen weeks. However, returning the bone strength and its ability to sustain a heavy load may take as long as up to a year [12]. Once we clinically and radiographically establish that the bone has healed, the patient may resume everyday activities. It is important to instruct the patient not to overload the leg until the full strength has been regained [12].

In the treatment of 130 tibiae, Koprivčić *et al.* [13] treated 125 surgically and 5 conservatively. A hundred and thirteen surgically treated fractures were treated with screws and plates, 9 with intramedullary osteosynthesis and 3 with external fixator [13]. Out of the 130 patients, 117 fractures (90.00%) healed without complications, 2 (1.54%) were malunited, 4 (3.08%) sustained infection, and pseudoarthrosis occurred in 3 patients (2.31%). In 4 patients (3.08%) osteosynthesis was insufficient [13].

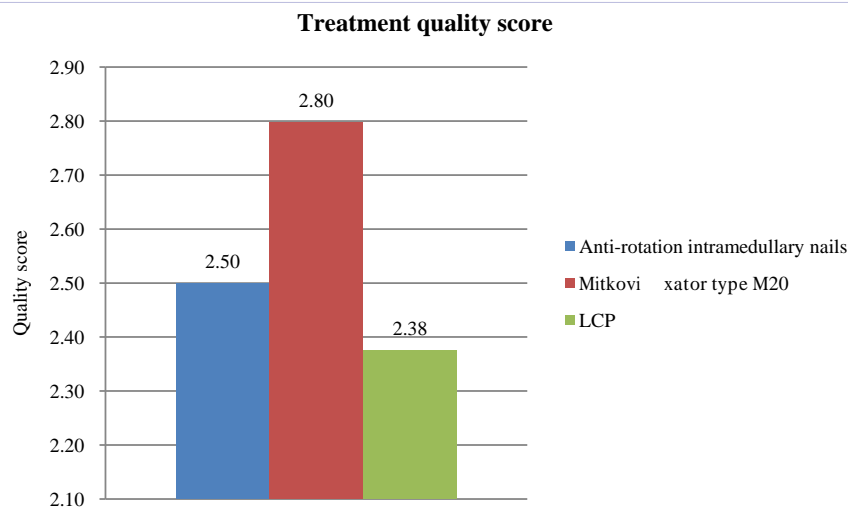


Figure 4: Treatment quality score.

The use of antibiotics is one of the key factors in the treatment of open tibial fractures [14]. In a prospective and retrospective study including 333 open tibial fractures, Gustilo decreased the rate of infections to 2.3% through the use of antibiotics, compared to 13.9% infections in the antibiotic-free group [4]. The choice of antibiotics should be based on the microbiological findings [14].

The dynamic LCP makes full access to the fracture possible, with no risk of infection [15]. The new generation of dynamic LCPs, which follow the angulation of the tibia, provide an adequate stability and offer new possibilities in tibial treatment, especially when used as 'internal fixators' [15]. The application of the dynamic LCP as an 'internal fixator' using a minimally invasive technique does not cause the compression of the implant onto the bone. This in turn provides biomechanical advantages: sufficient stability which allows a quick healing of the bone accompanied by a callus [15].

The locked intramedullary nail can serve as the gold standard for the treatment of open and closed tibial fractures [16]. When compared to the external fixator, there are no major differences in terms of the time necessary for the healing of the fractured bone or in terms of the infection rate [16].

Conclusion

The Mitković external skeletal fixator type M20 is unilateral, simple and efficient at treating all types of open, closed and unstable tibial diaphyseal fractures. This type of treatment facilitates safe fracture union, early mobilisation, rehabilitation and weight-bearing of the operated patient. The fracture fixation is unilateral with the pins oriented convergently, and there is a possibility of compression and distraction, which in the process of fracture healing gives a possibility to adjust to biomechanical conditions-by dynamisation of the instrument. It is re-usable, which makes the treatment cheaper.

The intramedullary nail with locking screws requires an extremely good surgical technique which is sensitive (delicate) and requires an adequate instrumentarium. It can be used for

the treatment of open, closed and segmental tibial fractures. The price of the instrument, two surgical interventions and the results of treatment with the locked intramedullary nail, compared to the M20, are statistically insignificant.

The dynamic DCP is indicated for closed fractures, it requires a solid surgical technique and an adequate instrumentarium. It cannot be used in segmental fractures due to the price, two surgical interventions required for complete healing, and the results, compared to the M20, are statistically insignificant.

Conservative treatment of tibial fractures is the method of choice in patients if the x-ray examination confirms that the fragments have an acceptable position for conservative treatment with plaster cast. This way we avoid any possible intraoperative and postoperative complications of surgical treatment. This type of treatment is the cheapest.

In the examined series, the Mitković external fixator type M20 is the method of choice in surgical treatment of tibial fractures. The locked intramedullary nail would take the second place, and the dynamic DCP would follow.

References

1. Bhandari M, Tornetta P, Sprague S, Najibi S, Petrisor B, Griffith L, et al. Predictors of reoperation following operative management of fractures of tibial shaft. *J Orthop/Trauma*. 2003; 17(5): 353-361.
2. Horas U, Popa RB, Kilian O, Stahl JP, Heiss C, Schnettler. Biorigid" interlocking after undreamed intramedullary nailing of tibial shaft fractures. *Unfallchirurg*. 2002; 105(9): 797-803.
3. Oh CW, Park BC, Kyung HS, Kim SJ, Kim HS, Lee SM, et al. Percutaneous plating for unstable tibial fractures. *J Orthop Sci*. 2003; 8(2): 166-169.
4. Gustilo RB, Mendez RM, Willams DN. Problems in the management of type III (severe) open fractures. A new classification of type III open fractures. *J Trauma*. 1984; 24(8): 742-746.
5. Mitković M. External fixation in the traumatology. Niš:Prosveta. 1992(in Serbian).
6. Karlstrom G, Olerud S. Fractures of the tibial shaft, a critical evaluation

- of treatment alternatives. *Clin Orthop*. 1974; 105: 82–115.
7. Blagojević Z, Diklić I, Stevanović V. Treatment of tibial oblique and spiral fractures using Enders' pins. *Acta Orthop Iugosl*. 2002; 33: 113–116(in Serbian).
 1. Grubor P, Grubor M, Golubović I, et al. Importance of External Fixation in Primary Treatment of War Wounds to the Extremities *Scientific Journal of the Faculty of Medicine in Niš*. 2011; 28(4): 225-233.
 8. Shaw DL, Lawton JO. External fixation for tibial fractures: clinical results and cost effectiveness. *J R Coll Surg Edinb*. 1995; 40(5): 344–346.
 9. Keating JF, Gardner E, Leach WJ, Macpherson S, Abrami G. Management of tibial fractures with the orthofix external fixator. *J R Coll Surg Edinb*. 1991; 36(4): 272– 277.
 10. Krettek C, Haas N, Tschern H. Results of treatment of 202 fresh tibial shaft fractures, managed with unilateral external fixation (monofixateur). *Unfallchirurg*. 1989; 92(9): 440–452.
 11. Chapman, Michael W. *Chapman's Orthopaedic Surgery*. 3rd ed. Philadelphia: Lippincott, Williams & Wilkins. 2001.
 12. Koprivčić I, Lovrić I, Kondža G, et al. Surgical treatment of tibial fractures. *Acta Chir Croat*. 2012; 9: 43-44.
 13. Neubauer T, Bayer GS, Ayer GS, Wagner M. Open Fractures and Infection. *Acta Chirurgiae Orthopacuae et Traumatologiae Česosl*. 2006; 73: 301–312.
 14. Wagner M. General principles for the clinical use of the LCP. *Injury*. 2003; 34S2: 31–42.
 15. Zalavras CG, Patzakis MJ. Open Fractures: evaluation and management. *J Amer Acad Orthop Surg*. 2003; 11(3): 212–219.